

Classification of Femoral Abnormalities in Total Hip Arthroplasty

JAMES D'ANTONIO, M.D.,* JOSEPH C. MCCARTHY, M.D.,** WILLIAM L. BARGAR, M.D.,†
LESTER S. BORDEN, M.D.,‡ WILLIAM N. CAPPELO, M.D.,§ DENNIS K. COLLIS, M.D.,||
MARVIN E. STEINBERG, M.D.,¶ AND JOHN H. WEDGE, M.D.#

Bony abnormalities of the femur can significantly complicate total hip arthroplasty both for the primary and revision operations. No standard nomenclature exists for the description of these femoral abnormalities. A classification system is presented to standardize nomenclature, assist in preoperative planning, and to assist in the reporting of these defects.

Reconstructive surgery of the femur is frequently complicated by the presence of bony abnormalities. These deformities include angular and versional distortions, changes in the medullary cavity of the femur, and loss of bone stock from the cortical pillars of the diaphysis. Although seen in primary cases, these abnormalities are particularly a problem in the revision situation. During the past 15

years, many authors have addressed the pathology and management of bony defects within the acetabulum.^{2,4-10} More recently, the American Academy of Orthopaedic Surgeons (AAOS) Committee on the Hip introduced a comprehensive classification system of these abnormalities.⁴ Complex deformities of the femur, both naturally occurring and after reconstructive surgery, are being seen in increasing numbers in recent years.^{2,3,5} This report represents the collaborate efforts of the AAOS Committee on the Hip to classify bony deficiencies of the femur in a uniform manner. This classification system is simple and is applicable to both primary and revision hip arthroplasty. An understanding of this system will facilitate both preoperative planning and surgical treatment of femoral bony deficiencies.

The essential terminology of this system is maintained from the acetabular publication⁴ to facilitate continuity. The principles of femoral reconstruction include equalization of leg lengths and balancing of muscle groups, particularly the abductor muscles, to restore the mechanics of the hip. In addition, restoration of femoral integrity, providing prosthetic containment, and rigid prosthetic fixation are goals of femoral reconstruction.^{1,2,5}

CLASSIFICATION OF FEMORAL ABNORMALITIES

The classification system of femoral abnormalities has two basic categories: segmental

* University of Pittsburgh School of Medicine, Pittsburgh, Pennsylvania.

** Tufts University School of Medicine, Boston, Massachusetts.

† Department of Orthopaedics, University of California at Davis School of Medicine, Sacramento.

‡ Section of Joint Replacement & Arthritis Surgery, Cleveland Clinic Foundation, Cleveland, Ohio.

§ Department of Orthopaedic Surgery, Indiana University School of Medicine, Indianapolis.

|| Division of Orthopaedics, Oregon Health Sciences University School of Medicine, Eugene.

¶ Department of Orthopaedic Surgery, Hospital of the University of Pennsylvania, Philadelphia.

Department of Surgery, University of Toronto, Toronto, Ontario, and Division of Orthopaedic Surgery, Hospital for Sick Children, Toronto, Canada.

Reprint requests to James A. D'Antonio, M.D., 1099 Ohio River Blvd., Sewickley, PA 15143.

Received: June 27, 1990.

Received: February 10, 1993.

Accepted: February 10, 1993.

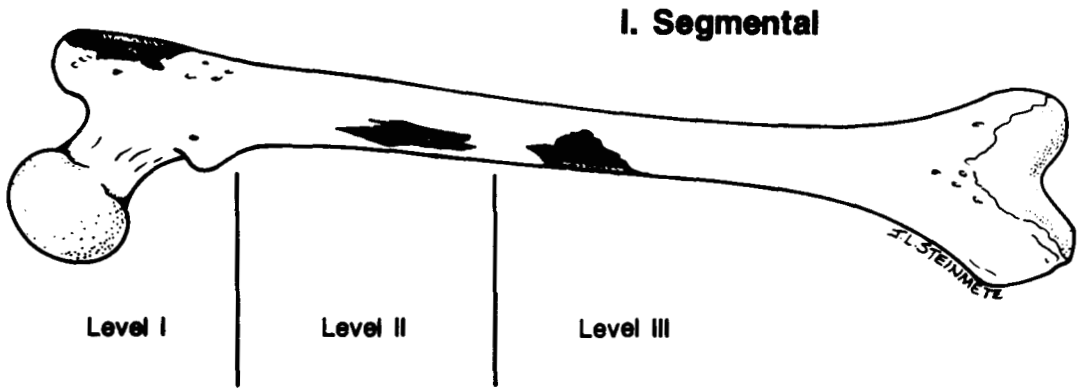


FIG. 1. Segmental defect: a loss of femoral cortical bony support. This may occur at Level I (above lower end of lesser trochanter), Level II (within 10 cm of lower edge of lesser trochanter), or Level III (distal to 10 cm below lower edge of lesser trochanter).

and cavitory. As described for the acetabulum, a segmental defect is defined as any loss of bone in the supporting cortical shell of the femur (Fig. 1). A cavitory defect is a contained lesion and represents an excavation of the cancellous or endosteal cortical bone with no violation of the outer cortical shell of the femur. Ectasia is an enlargement of the femoral medullary canal often associated with thinning of the diaphyseal cortex (Fig. 2).

tial segmental bone loss can be located anteriorly, medially, or posteriorly and can exist from proximal through any distal level of the femur. An intercalary defect is segmental cortical bone loss with intact bone above and below (*i.e.*, a cortical window). The greater trochanter is listed as a separate segmental defect because of the unique and difficult problems that it can present in femoral reconstruction. Segmental defects may occur alone or exist in combination with other deficiencies.

Segmental proximal deficiencies can be further subdivided into partial or complete. Par-

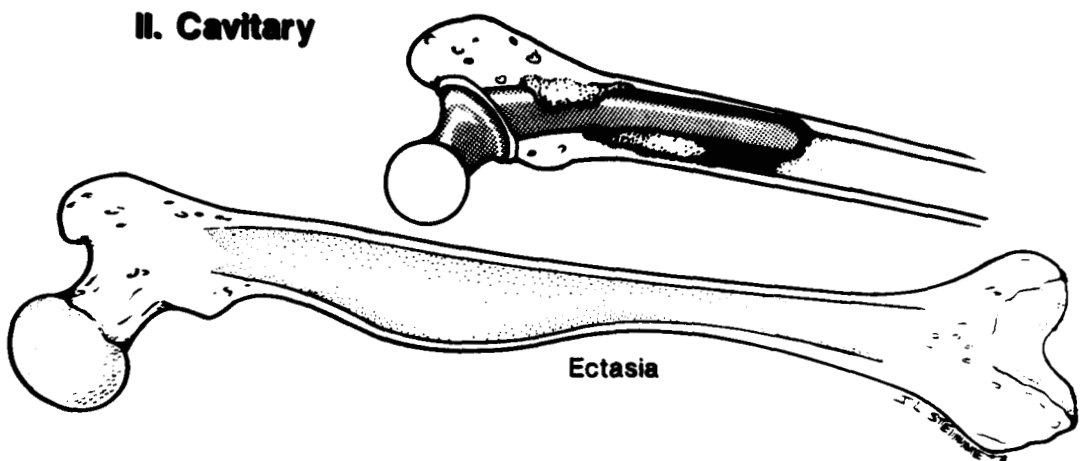
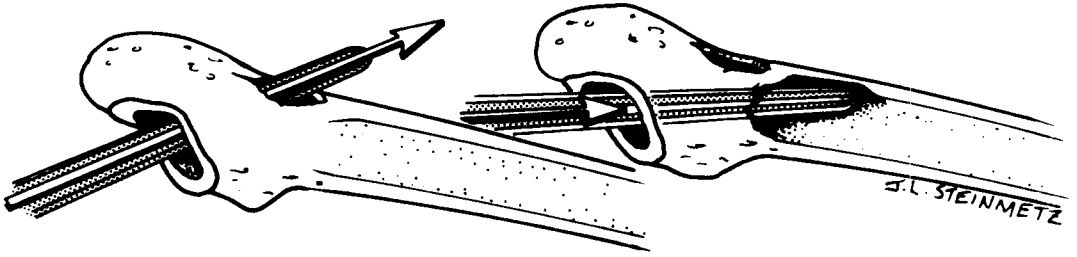


FIG. 2. Cavitory defect: a loss of cancellous or endosteal cortical bone without violation of the outer cortical shell. Ectasia is a form of cavitory defect in which the femoral medullary cavity is expanded.



III. Combined

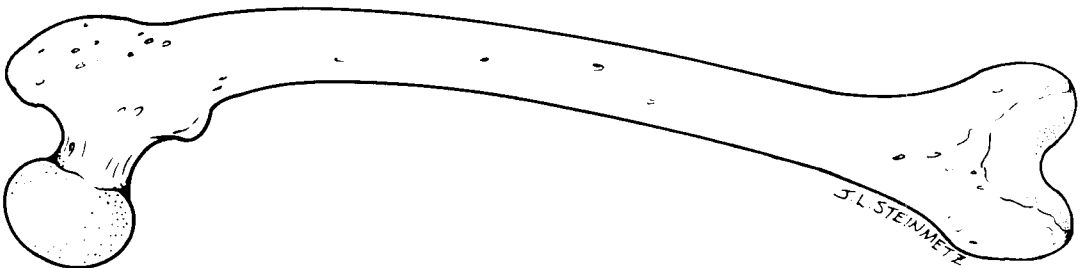
FIG. 3. Combined defects: a combination of segmental and cavitory bone loss in the femur. This may result from osteolysis, stem movement, or iatrogenic circumstances.

Cavitory defects are classified according to the degree of bone loss within the femur. Cancellous cavitory defects involve only the cancellous medullary bone. Cortical cavitory defects suggest a more severe type of erosion where, in addition to cancellous loss, the femoral cortex is eroded from within. Finally, in its extreme, the femur may become ectatic or dilated and show complete loss of cancellous bone, as well as severe cortical erosion and thinning.

A separate category of combined defects designates the situation where segmental and cavitory abnormalities co-exist (Fig. 3). For example, in cases of failed femoral implants, a proximal partial segmental defect involving the calcar to the level of the lesser trochanter

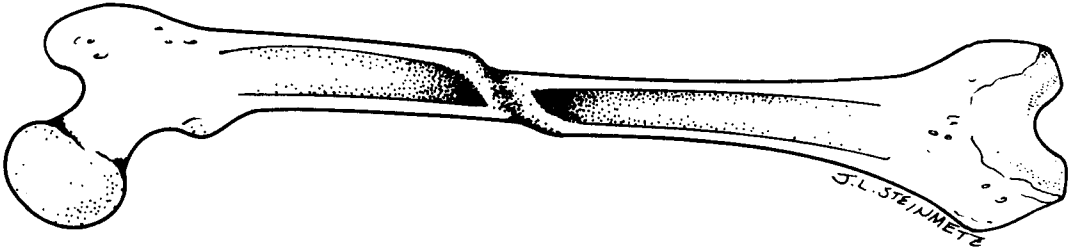
frequently co-exists with a cavitory defect in the medullary canal of the diaphysis. This proximal combined segmental and cavitory defect is the most common defect experienced in revision surgery, often the result of osteolysis and femoral stem subsidence into varus.

Next, the classification system addresses malalignment abnormalities. These distortions can be either in a rotational or angular direction (Fig. 4). Femoral stenosis is a separate category and involves the relative or absolute narrowing of the femoral canal (Fig. 5). Finally, femoral discontinuity describes the lack of bony integrity that exists with fractures of the femur with or without an implant present (Fig. 6).



IV. Malalignment

FIG. 4. Malalignment: a distortion of the femoral architectural geometry in either the rotational or angular plane.



V. Femoral Stenosis

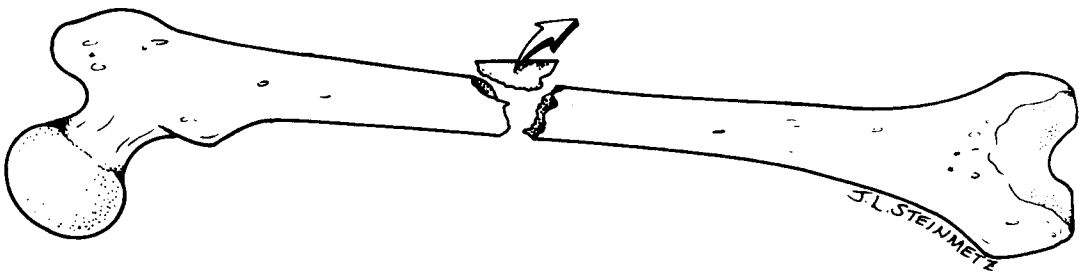
FIG. 5. Femoral stenosis: a partial or complete occlusion of the femoral intramedullary canal. This may result from bony hypertrophy, fracture, or fixation devices.

LEVEL OF BONE LOSS

To better localize the defects and assist pre-operative planning, levels of involvement are given (Fig. 1). Level I is defined as bone proximal to the inferior portion of the lesser trochanter. Level II is from the inferior lesser trochanter to 10 cm distal, and Level III involves bone distal to Level II. The inferior border of the lesser trochanter was chosen as a dividing line because defects below the superior border require special techniques for reconstruction. Most defects associated with failed primary femoral implants are incorporated within Level I or Level II areas. Level III deficiencies represent the most extreme form of involvement. They are usually the result of failed long-stem prostheses or from fracture of the femur.

GRADING SYSTEM

When reporting results using cementless femoral implants, it is important to grade the reconstructive effort. The grading system used here applies in primary hips, but is especially applicable in the revision surgical situation. Grade I is that circumstance where there is complete prosthetic host bone contact and no bone graft is required. A Grade II reconstruction implies incomplete prosthetic host bone contact where the prosthesis is stable in host bone and filler or particulate graft is not necessary for stability but may be added to fill the gaps. Grade III represents the greatest deficiency. There is incomplete prosthetic host-bone contact, and structural bone grafting is required (such as a proximal femoral allograft).



VI. Femoral Discontinuity

FIG. 6. Femoral discontinuity: a loss of femoral bony integrity, usually the result of fracture nonunion.

TABLE 1. Preoperative Planning

I. Classify bone defect
Plain radiographs
CT scan
Intraoperative inspection
II. Estimate size and biomechanical significance of defects
III. Evaluate bone quality
IV. Templating
Determine prosthetic size including length
Bypass intercalary defects by 2-1/2 canal diameters when possible
Restore head/neck offset and leg length

PLANNING FOR FEMORAL RECONSTRUCTION

Table 1 outlines the essential features in planning for femoral reconstruction. Standard AP and lateral radiographs, along with obliques of the entire femur, are necessary to identify the femoral deficiencies present in a revision case. It is advantageous to perform these films with magnification markers. Computed tomographic (CT) scanning of the proximal femur with or without three-di-

mensional reconstruction as well as CT-generated foam models can be used to elucidate complex deficiencies (Fig. 7) if no implant is present. Ultimately, intraoperative inspection, at times in conjunction with intraoperative radiographs, fully defines the femoral abnormalities. Other preoperative studies, such as hip aspiration or scintigraphy, help to determine the presence or absence of infection.

Preoperative planning serves to shorten the surgical learning curve, evaluate the quality and quantity of femoral bone available for reconstruction, and establish a mechanism for the restoration of normal hip mechanics. Templating of the femur in both the AP and lateral planes is essential to determine prosthetic size and length. When intercalary defects are present, planning should include bypassing those defects by two and one-half canal diameters. This is particularly important in cemented arthroplasty. The appropriate head/neck offset should be used to restore leg length and the hip abductor muscle arm. When bone destruction has occurred in the proximal femur, remnants of the lesser trochanter or the tip of the greater trochanter

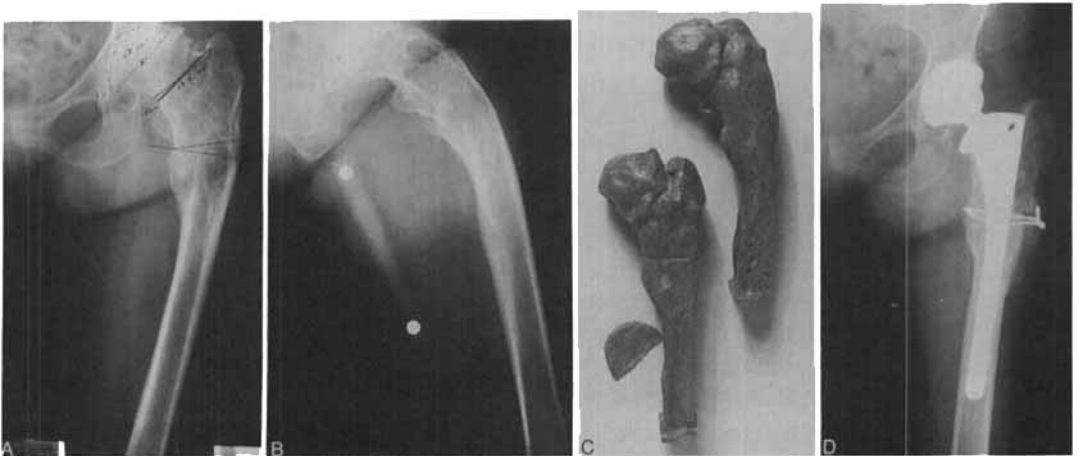


FIG. 7A-7D. (A) AP radiograph of the left hip in a 61-year-old woman with malunited intersubtrochanteric fracture and secondary degenerative joint disease. (B) Lateral preoperative radiograph of the left hip. (C) CT-scan-generated foam models to assist in preoperative planning. (D) Postoperative radiograph shows completion of the two-plane derotational osteotomy to correct varus, posterior angulation, and retroversion. A collared cementless prosthesis with onlay autograft was used for fixation of the osteotomy, which healed within eight weeks.

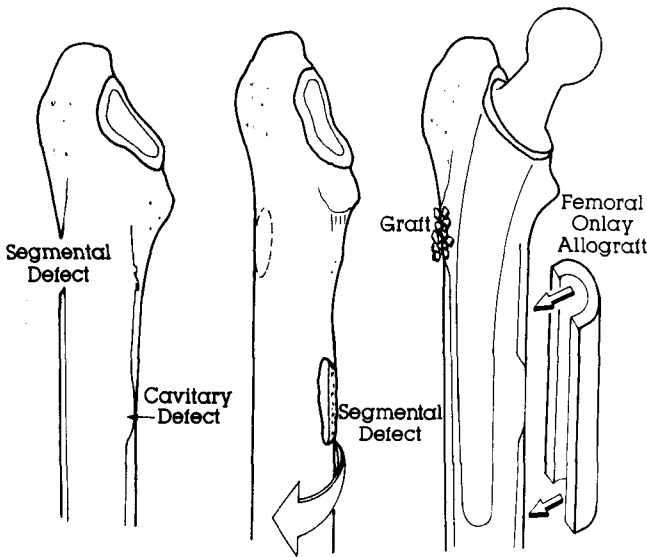


FIG. 8. A 68-year-old patient with combined segmental and cavitary femoral defects associated with a prior girdlestone resection procedure. Preoperative planning includes recognition of these defects, choosing an implant that bypasses the areas of bone loss, and planning for an onlay femoral allograft to restore bone stock.

can be used as a landmark for templating. Templates for both standard length and long-stem curved and straight-stem implants must be available to best determine the most appropriate prosthetic implant.

Current devices available for femoral reconstruction include cemented stems of standard length, long length, and cemented stems for proximal femoral replacement. In addition, cementless stems, both proximally porous coated and more extensively porous coated, are available in standard-length straight stems, curved stems, long straight stems, and long curved stem designs. More recently, custom and modular prostheses have become available. Finally, each of the above designs can be found with and without a collar.

In addition to the implant chosen, femoral reconstruction often involves bone grafting. This bone may consist of autograft from the iliac crest or femoral head if available. Alternatively, allograft bone may be necessary to bridge large segmental defects or fill cavitary lesions. This allograft material may be in the form of a proximal femur, distal femur, femoral diaphysis, proximal tibia, fibular struts, or femoral head. Rigid fixation of the allograft

to host bone often involves ancillary fixation devices such as screws, plates, wires, or cables.

Once the defects have been defined, templating has determined the most appropriate implant, and special needs, such as bone grafts, plates, or cables, have been determined, surgical plans can be fully formulated (Fig. 8). An important part of this plan includes the surgical approach where one must also correlate acetabular bone deficiency when selecting either an anterior, posterior, transtrochanteric, or trochanteric slide approach. When bone grafting is anticipated for the acetabulum and femur, provisions should be made for extensive exposure of both the pelvis and the femur.

The classification system as presented is simple and straightforward and yet covers the range of defects seen both in the primary and revision setting. This system provides a common language for the planning and reporting of surgical reconstructions.

REFERENCES

1. Bargar, W. L., Paul, H. A., Merritt, K., and Sharkey, N. The calcar bone graft. *Clin. Orthop.* 202:269, 1986.
2. Chandler, H. P., and Penneberg, B. L.: Bone Stock

- Deficiency in Total Hip Replacement. Slack, Thorofare, New Jersey, 1989.
3. D'Antonio, J. A., Steinberg, M. E., Collis, D. K., Haddad, H. J., Jr., Stulberg, S. D., Wedge, J. H., and Bargar, W. L.: Classification and Management of Femoral Defects. Exhibit, 57th Annual Meeting of the AAOS, New Orleans, February 1990.
 4. D'Antonio, J. A., Capello, W. N., Borden, L. S., Bargar, W. L., Bierbaum, B. F., Boettcher, W. G., Steinberg, M. E., Stulberg, S. D., and Wedge, J. H.: Classification and management of acetabular abnormalities in total hip arthroplasty. *Clin. Orthop.* 243:126, 1989.
 5. Gross, A. E., Laoie, M. V., McDermott, P., and Marx, P.: The use of allograft bone in revision of total hip arthroplasty. *Clin. Orthop.* 197:115, 1985.
 6. Harris, W. H.: Allografting in total hip arthroplasty. *Clin. Orthop.* 162:150, 1982.
 7. McCarthy, J. M.: Classification and Management of Bone Deficiencies About the Hip in Total Hip Replacement. Exhibit, 58th Annual Meeting of the AAOS, Anaheim, CA, March 1991, and at the 59th Annual Meeting, Washington, DC, February 1992.
 8. McGann, W., Mankin, H. J., and Harris, W. H.: Massive allografting for severe failed total hip replacement. *J. Bone Joint Surg.* 68A:1, 1986.
 9. Pellicci, P. M., Wilson, P. D., Jr., Sledge, C. B., Salvati, E. A., Ranawat, C. S., and Poss, R.: Revision total hip arthroplasty. *Clin. Orthop.* 170:34, 1982.
 10. Ranawat, C. S., Dorr, L. D., and Englis, A. E.: Total hip arthroplasty in protrusio acetabulae of rheumatoid arthritis. *J. Bone Joint Surg.* 62A:1059, 1980.