

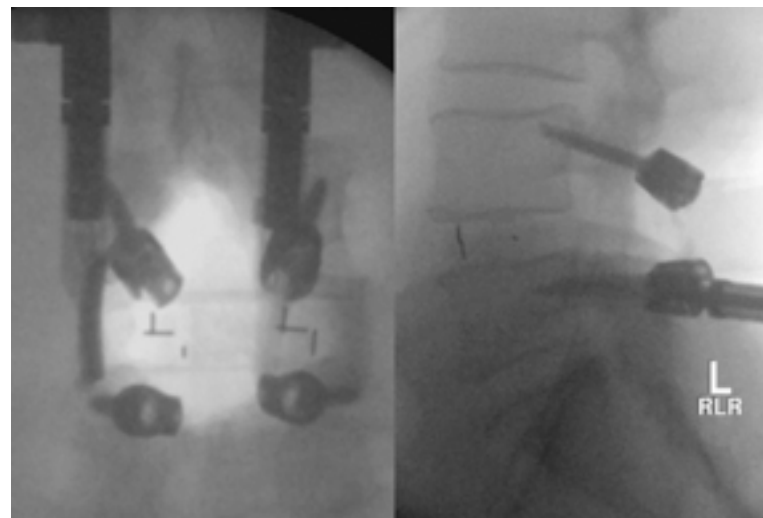
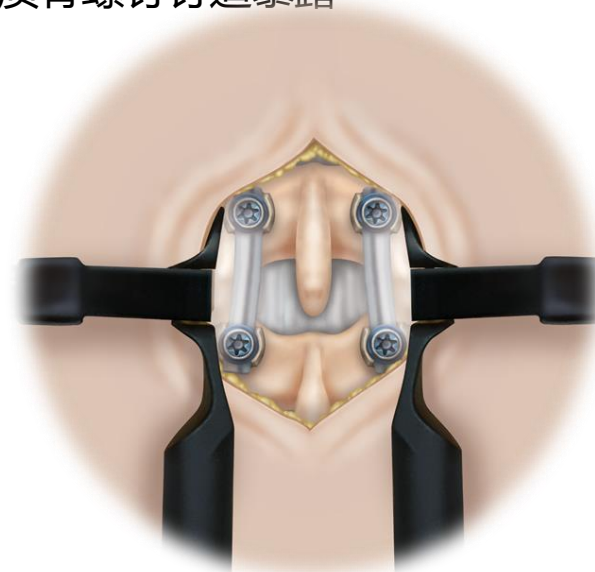
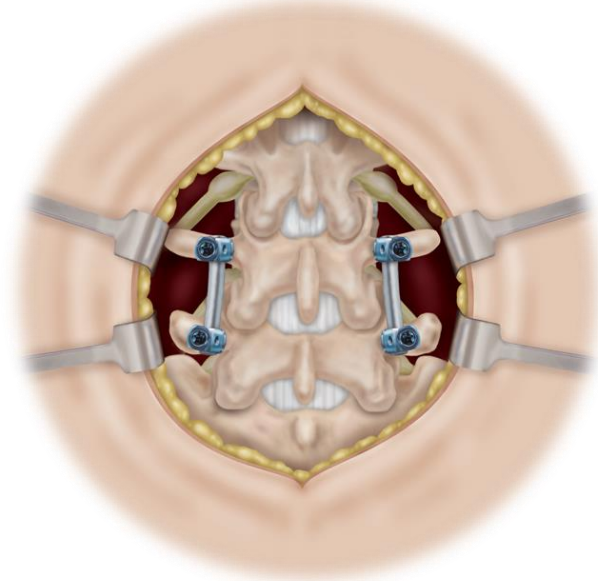
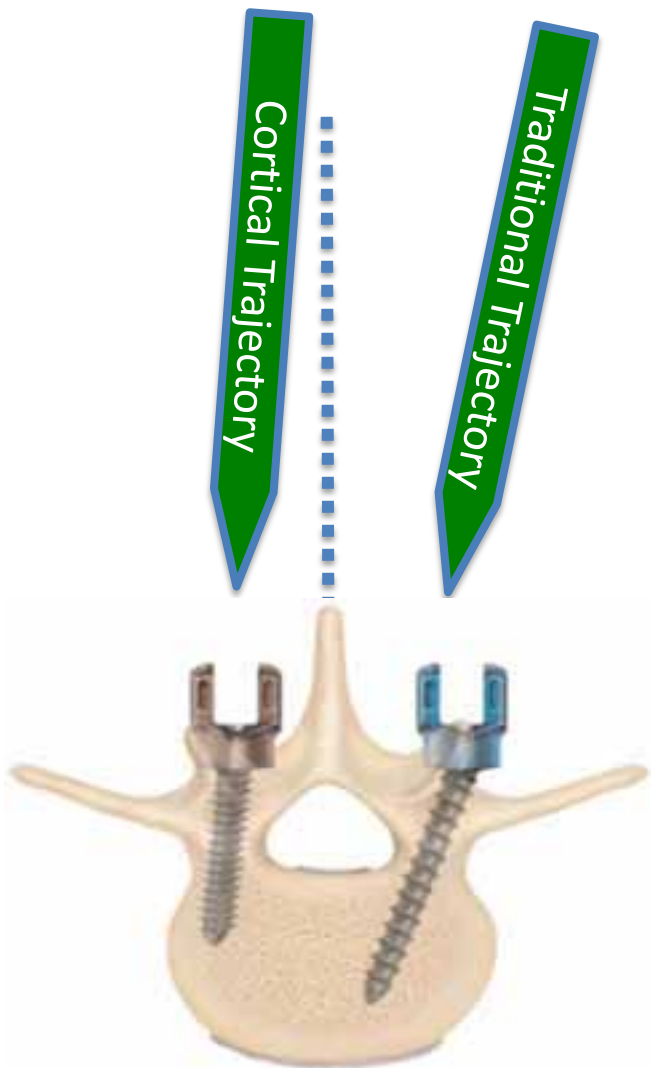
# 脊柱皮质骨螺钉中线固定及融合技术

**(MAST MIDLF手术技术)**

# What is MIDLF? 概念

Open Exposure  
传统椎弓根螺钉暴露切口


MIDLF  
皮质骨螺钉钉道暴露



# Thread Pattern: Cortical Screw

## 皮质骨螺钉螺纹

Cortical



Traditional

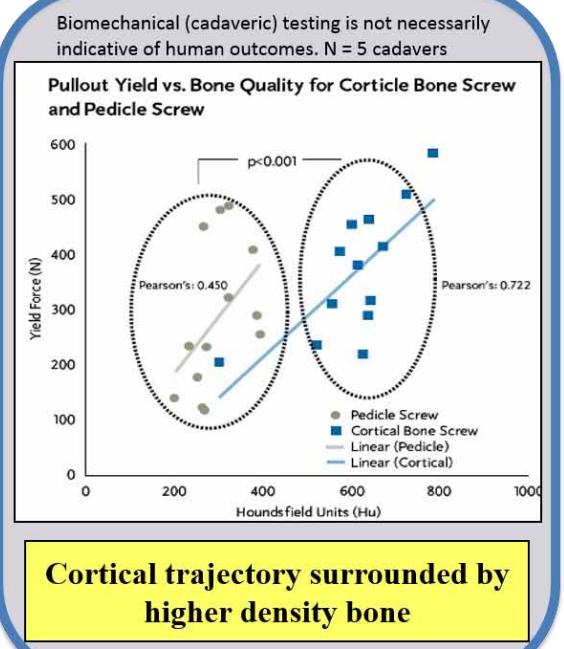
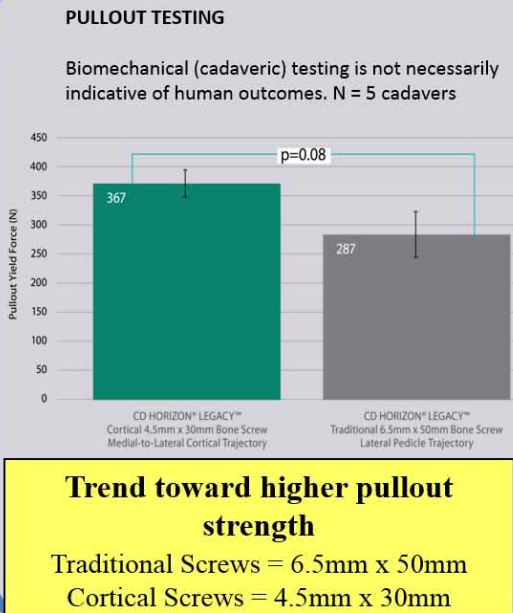
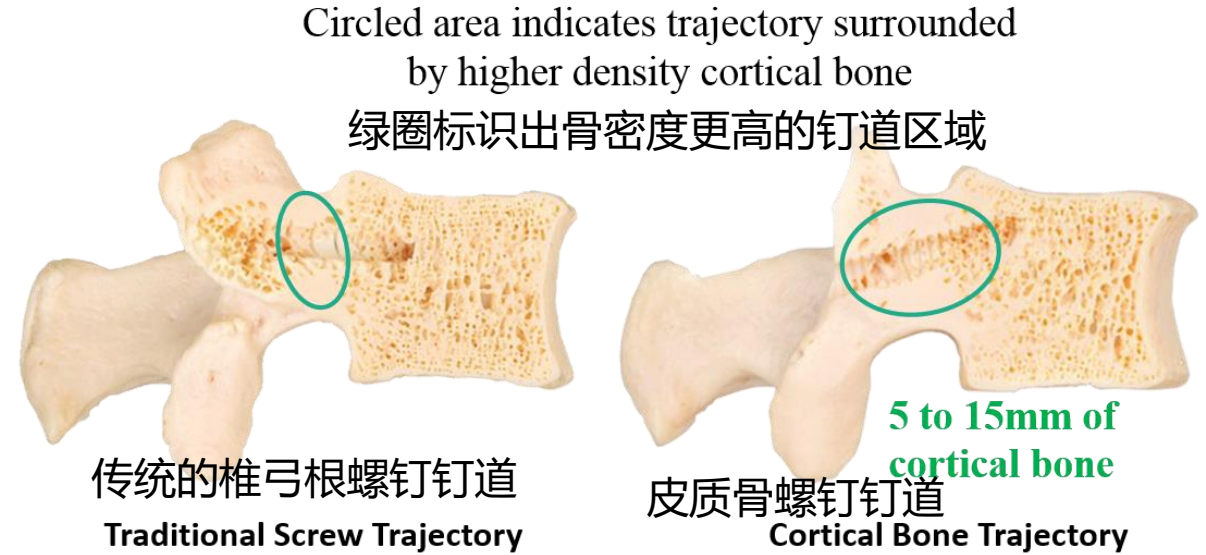
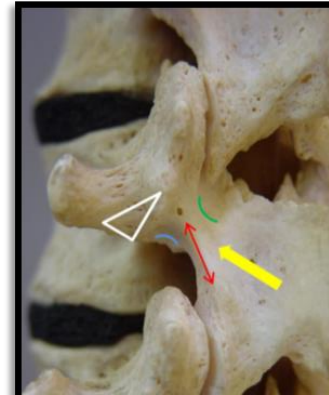
- **Screw Diameters are 4.0, 4.5, 5.0 & 5.5** 螺钉直径
  - (Common Diameter is 5.0) 常用
  - 6.5 and 7.5 Diameter Screws are Available 同样可用
- **Screw Lengths are 15mm, 20mm, 25mm & 30mm** 螺钉长度
  - (Common Length 25mm) 常用



Cortical  
Thread  
皮质骨螺纹

- **I use Solera Screws: 5.5x30**
- **for lumbar, 7.5x35 for sacral**  
我的常用尺寸，腰椎5.5\*30，骶骨7.5\*35

# Strong Screw 把持力更强的螺钉



Santoni BG, et al. Cortical bone trajectory for lumbar pedicle screws. *Spine J.* 2008 Sep 12.

Biomechanical Analysis of TLIF Constructs with Cortical versus Pedicle Bilateral Screw-Rod Fixation  
 Edward K. Nomoto, MD<sup>1</sup>, Alexandre Rasouli, MD<sup>2</sup>, Guy R. Fogel, MD<sup>3</sup>, Alexander W. Turner, PhD<sup>4</sup>; 1Harbor-UCLA Medical Center, La Jolla, CA, US; 2Los Angeles, CA, US; 3Spinepainbegone, San Antonio, TX, US;

Proceedings of the NASS 29th Annual Meeting / The Spine Journal 14 (2014) 1S–183S

**CONCLUSIONS:** Supplemental fixation of a single-level TLIF construct with either pedicle or cortical screws provided significant reductions in ROM in flexion-extension and lateral bending compared to the intact condition. *There were no statistically significant differences between the 2 fixation methods in any of the directions tested*

# Overview of the Technique 技术总览

## Exposure 暴露

- Midline laminectomy exposure to facet joints 暴露至关节突
- May or may not remove spinous processes 不一定需要移除棘突

## Trajectory 钉道

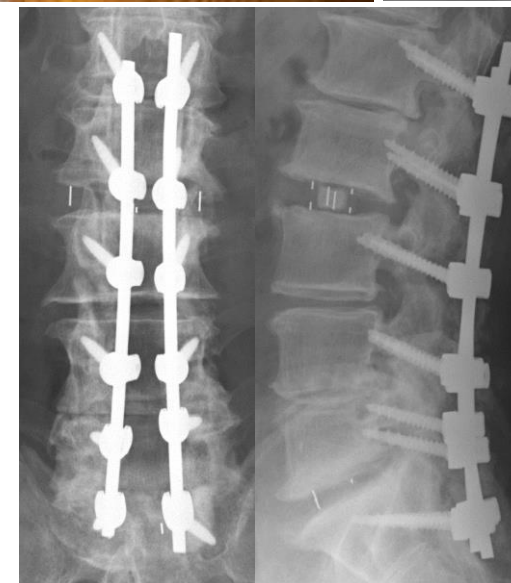
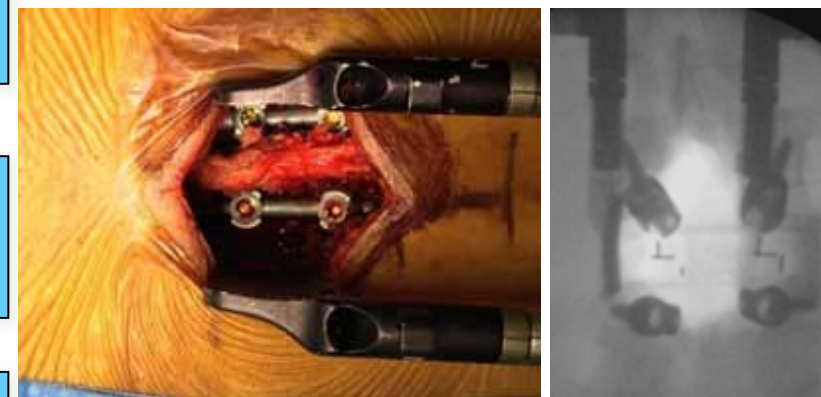
- Similar to Cervical Lateral mass screws 类似于颈椎侧块螺钉

## Decompress 减压


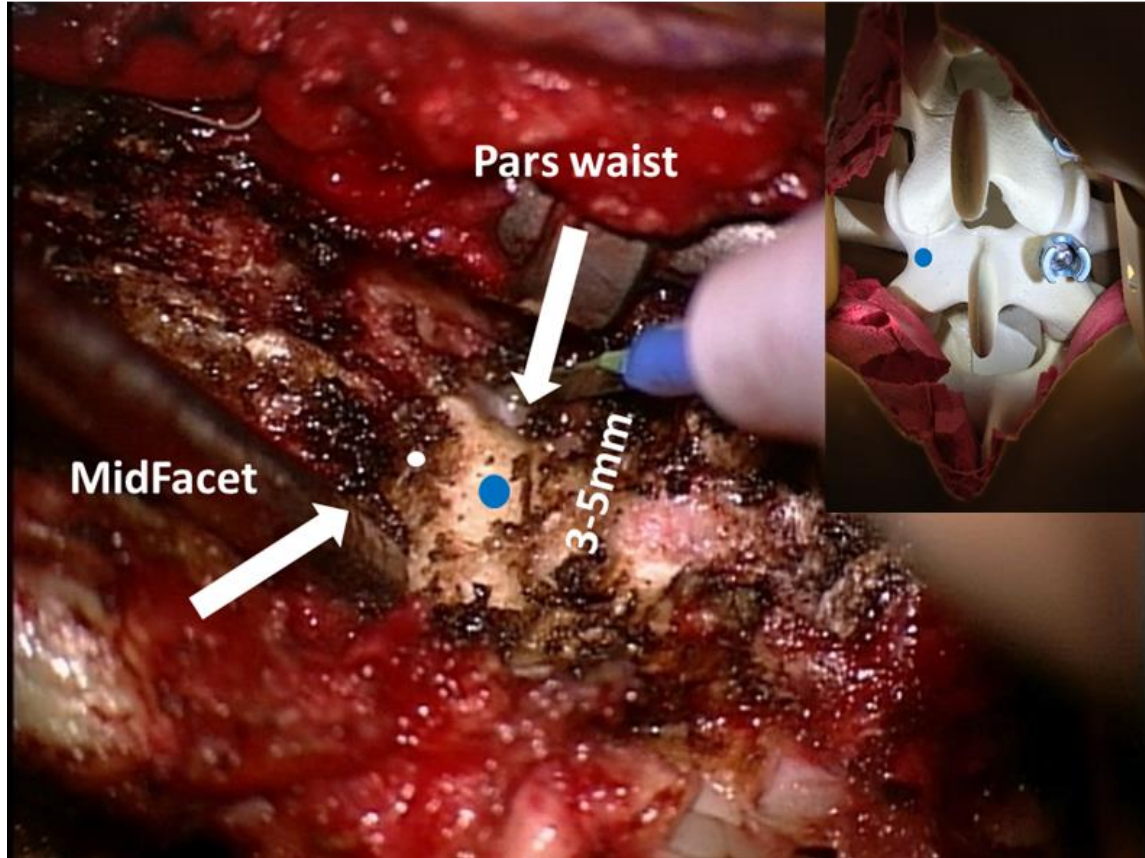
- Prepare trajectory before laminectomy, Insert after laminectomy 开钉道后减压, 最后置钉
- Keep 3 mm bone around screw 钉道周围保留3mm骨质

## Adjunct to Fusion 融合

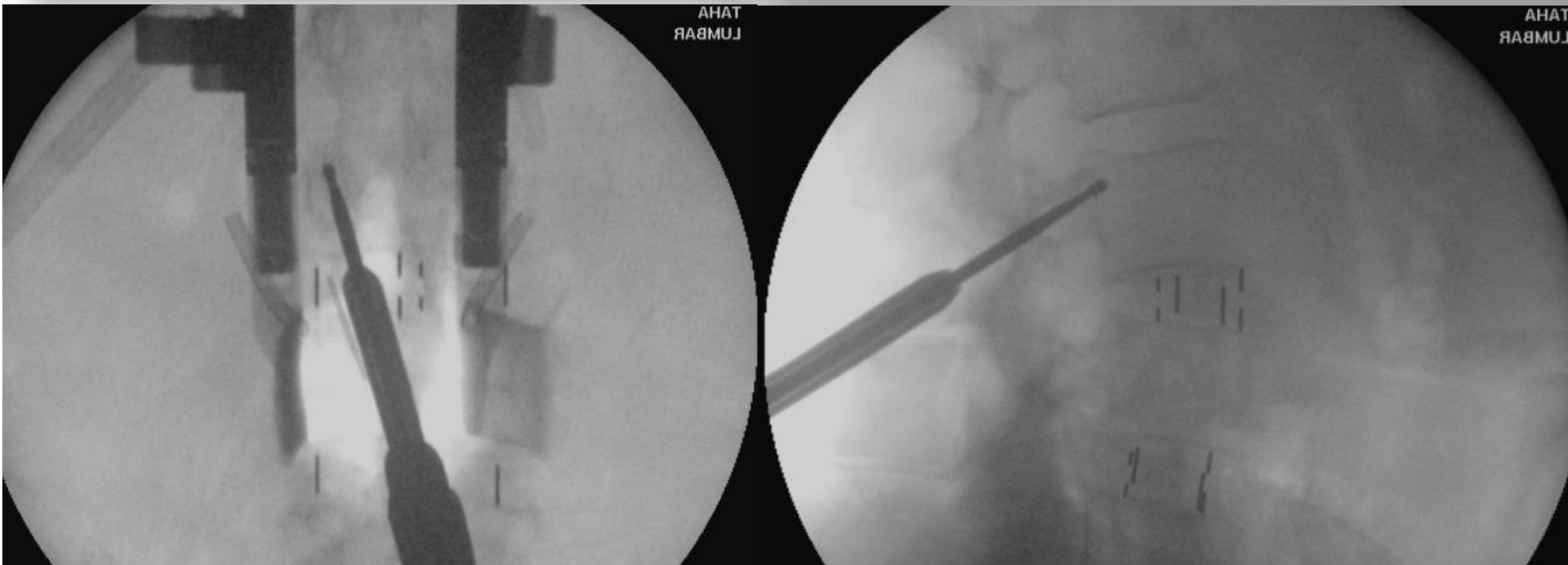
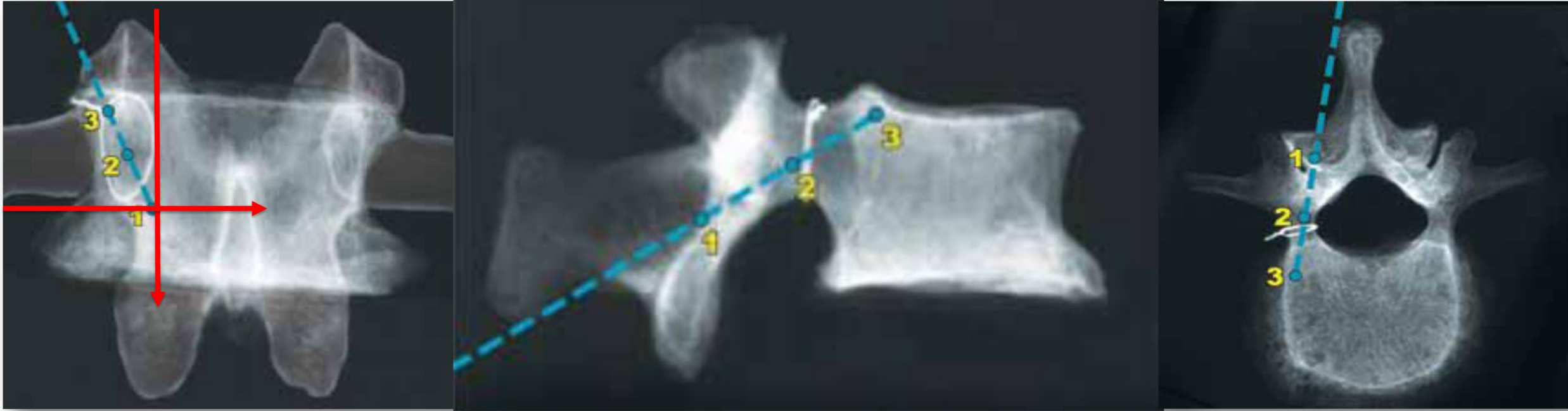
- Can do TLIF, PLIF, PL or adjunct to OLIF 多种融合途径



# Technique: Starting Point & Trajectory 进针点及钉道

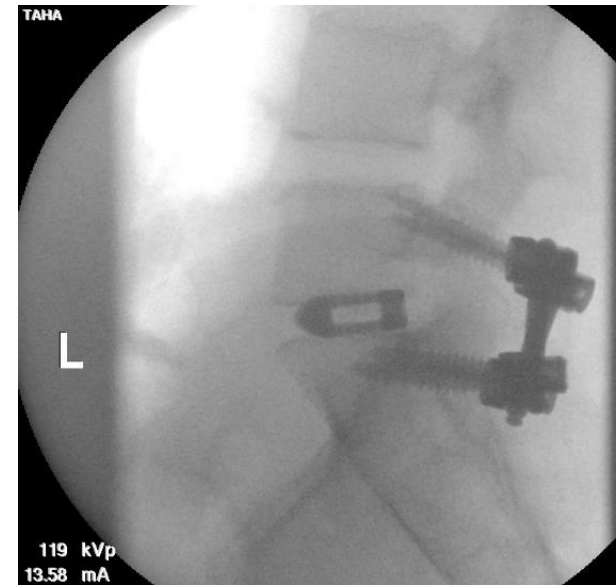
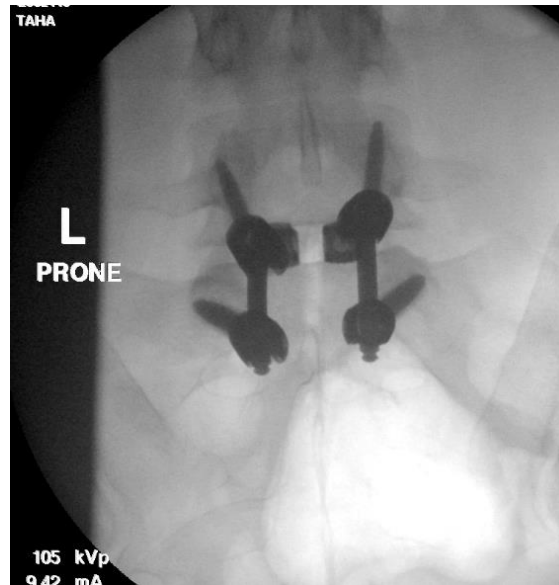
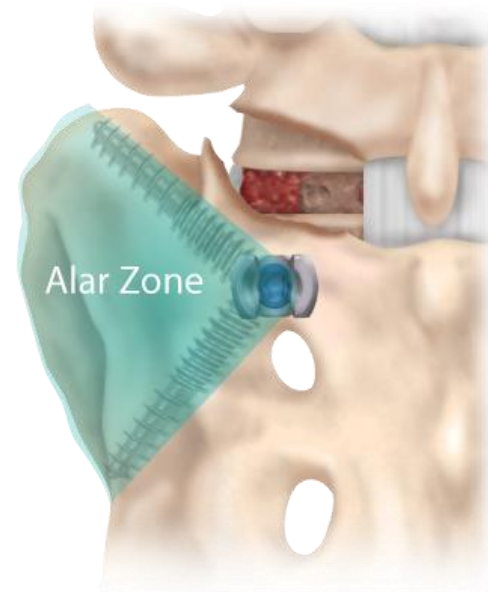
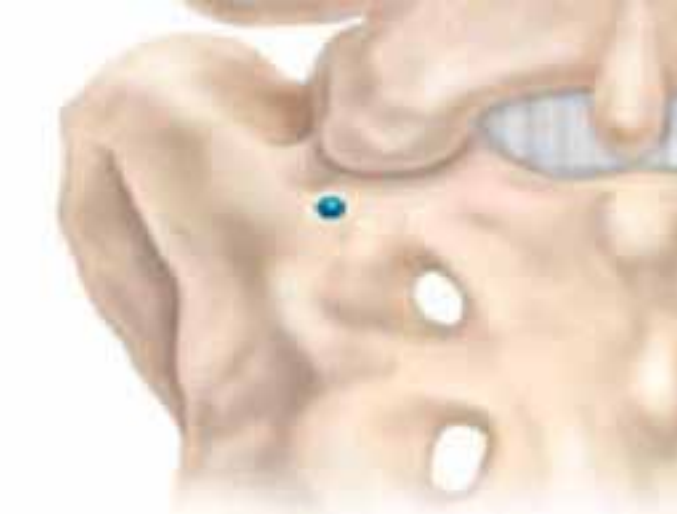

# Technique: Starting Point & Trajectory 进针点及钉道



- ✓ Orthogonal AP View
- ✓ Drill to midpoint of pedicle then switch to lateral or AP 磨钻朝向椎弓根的中点再向外侧

# S1 Screw Options: Alar Trajectory 骶1螺钉





# Sequential Steps 操作步骤

## Drill 磨钻

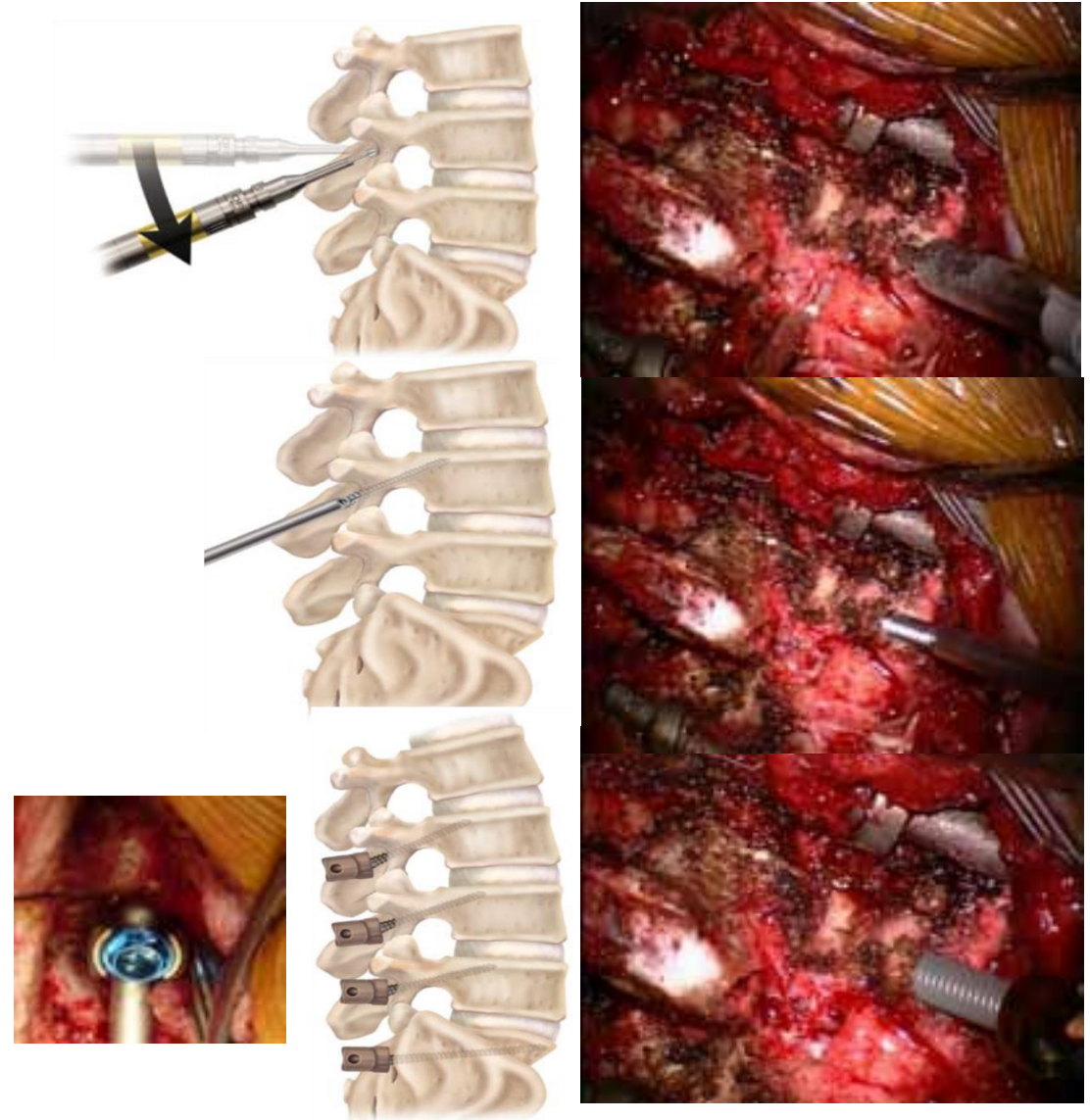
- Use Matchstick bit & irrigation 使用火柴头磨钻并不断冲洗
- Use 2 hands for pure cortical 双手持钻推进
- The center canal is medial, the exiting nerve root is caudal 脊髓在中间位置, 出口根在尾端, 有效避开神经
- Slight tapping of “Pistoning” is helpful 活塞式推进

## Tap 丝攻

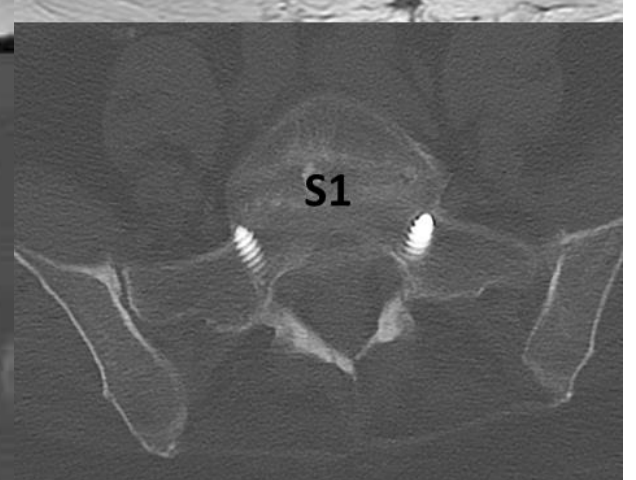
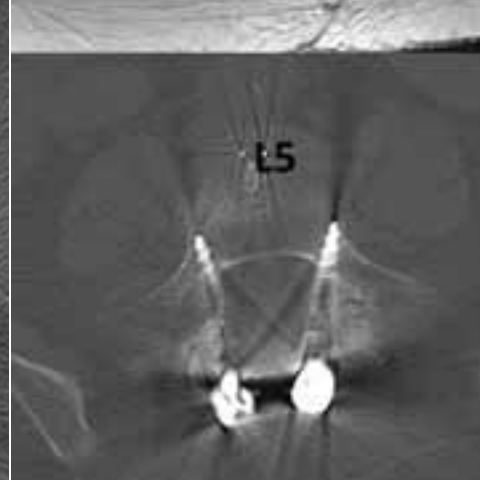
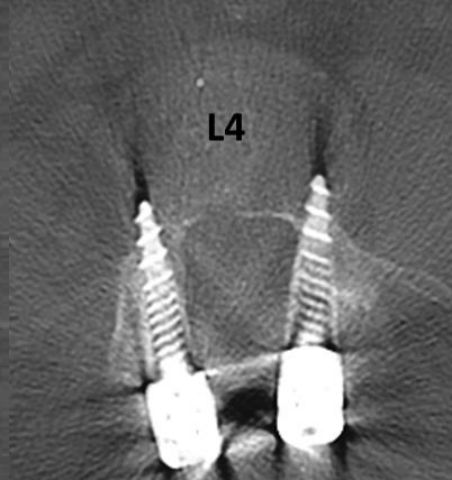
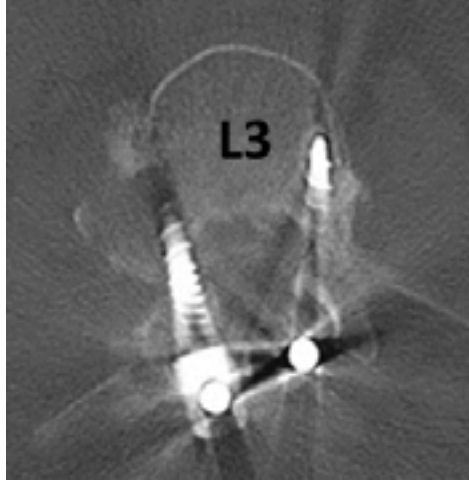
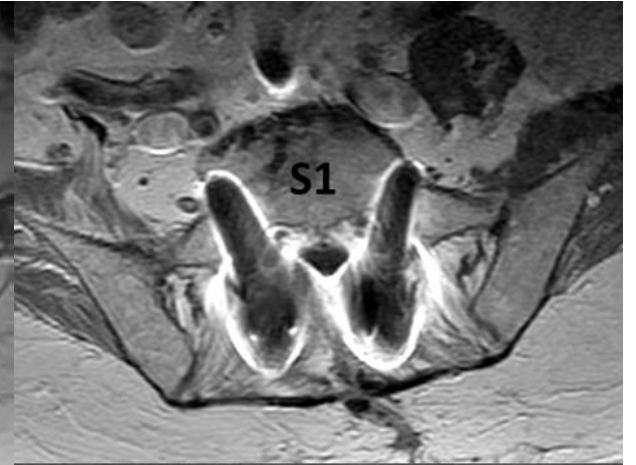
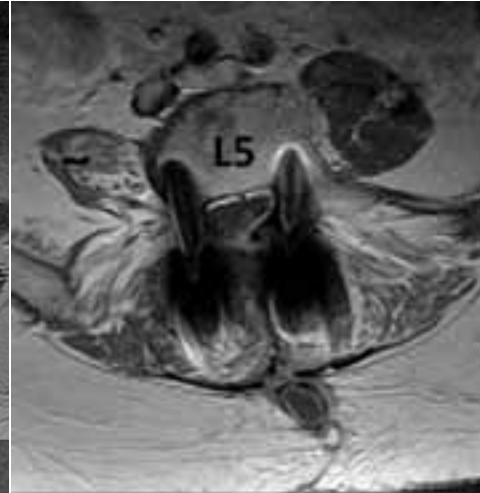
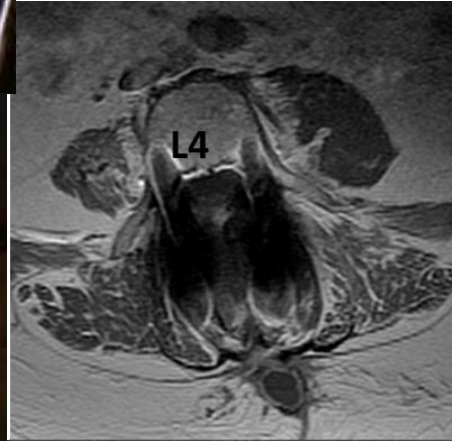
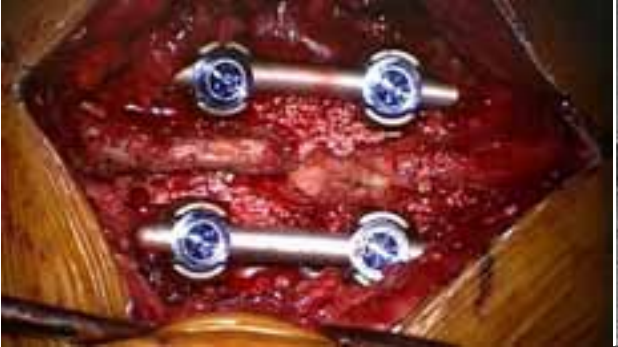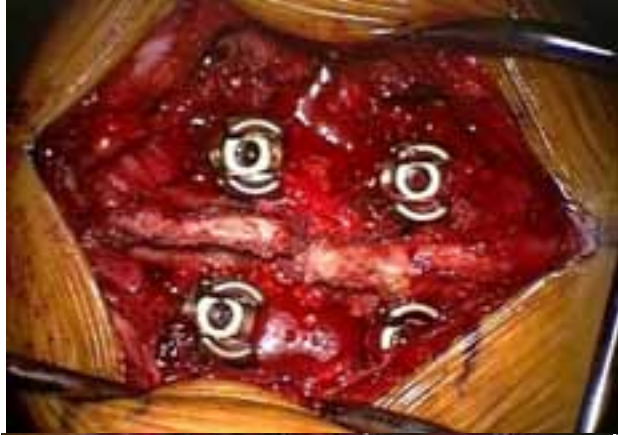- Tap entire trajectory 需丝攻整个钉道
- Can use PowerEase 可搭配使用动力系统

## Screw 置钉

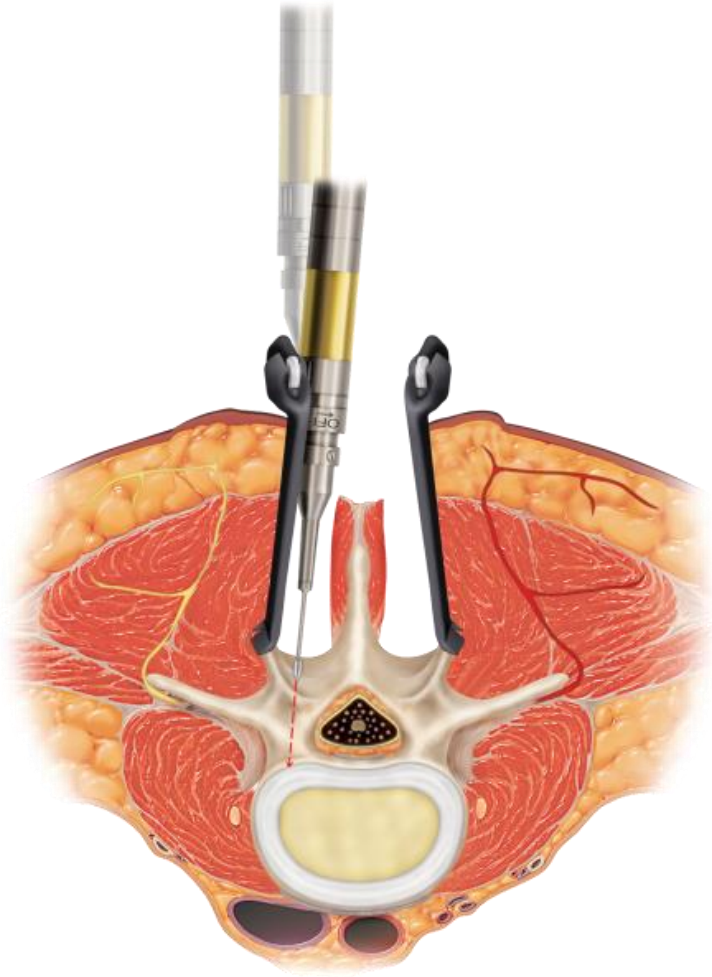
- Can use PowerEase 可搭配使用动力系统
- Leave rostral screw slight proud so it dose not dig into facet. 头端螺钉置钉时可预留与骨质空间, 防止同小关节发生撞击
- Screw head should not be buried onto laminae or spinous process 钉头应注意不被椎板或棘突阻挡



# Final Appearance 最终影像



# MIDLF: Access Instrumentation 通道工具



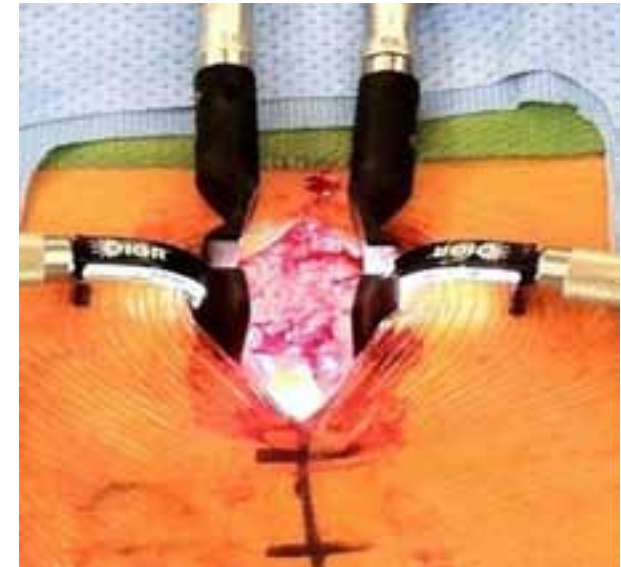
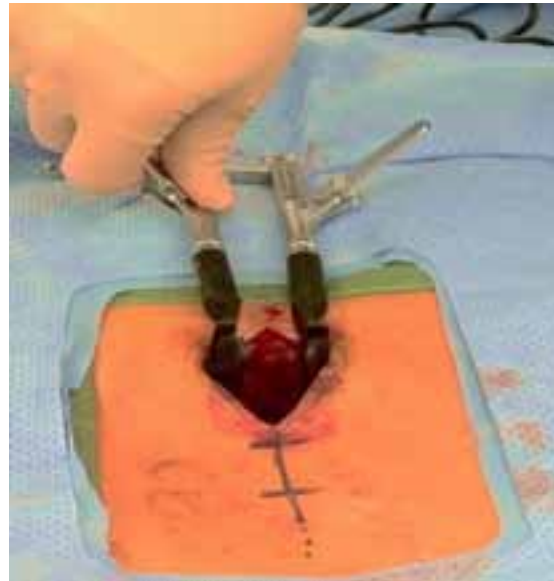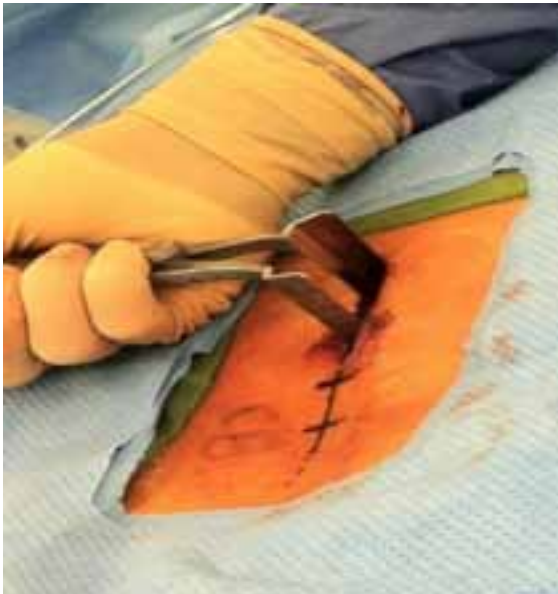
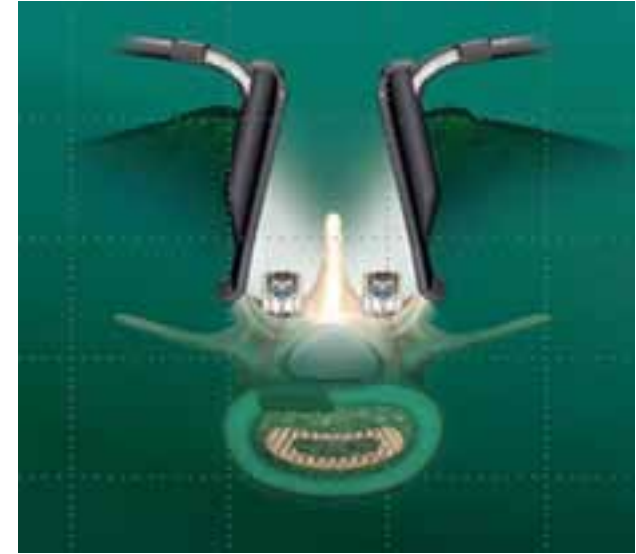
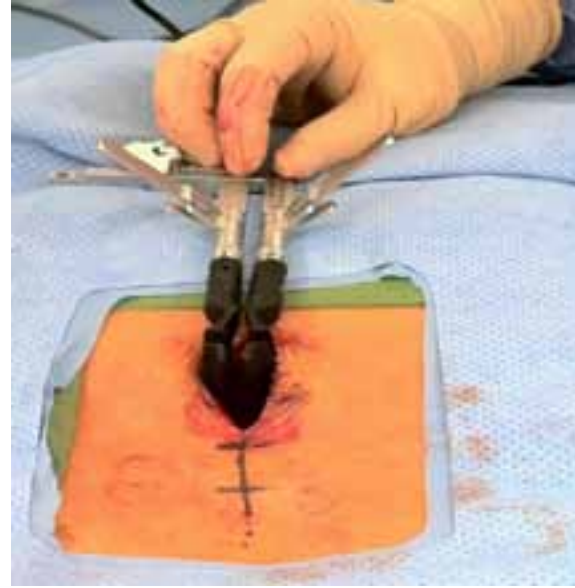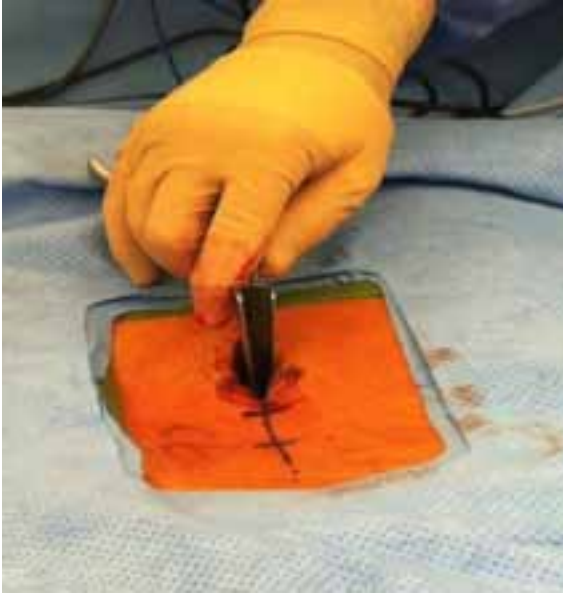
Midline Blades  
(4cm to 11cm)



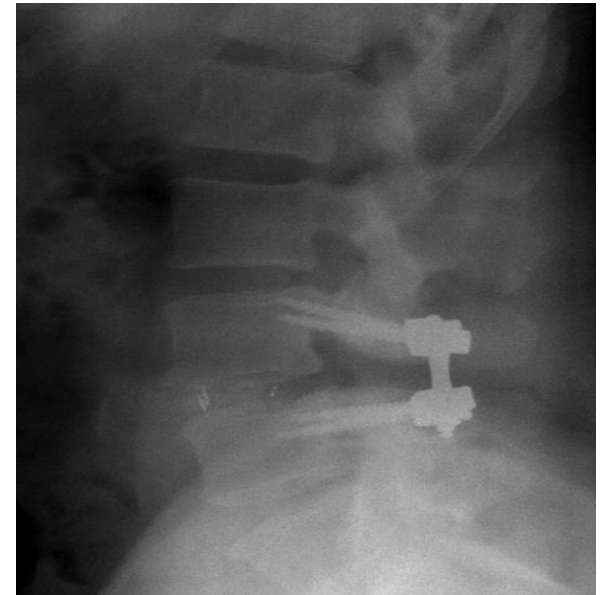
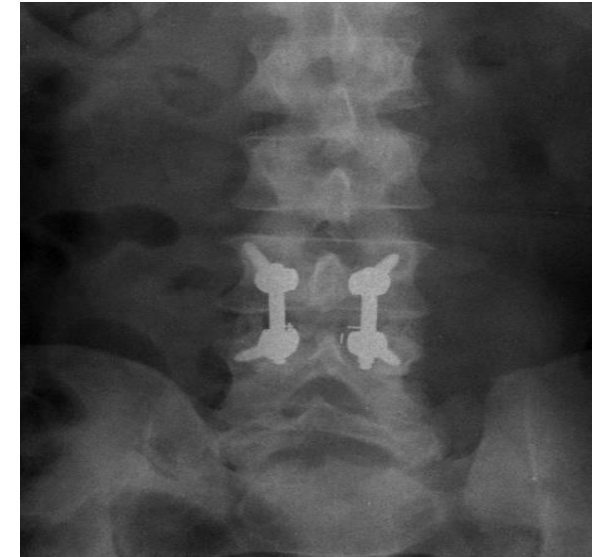
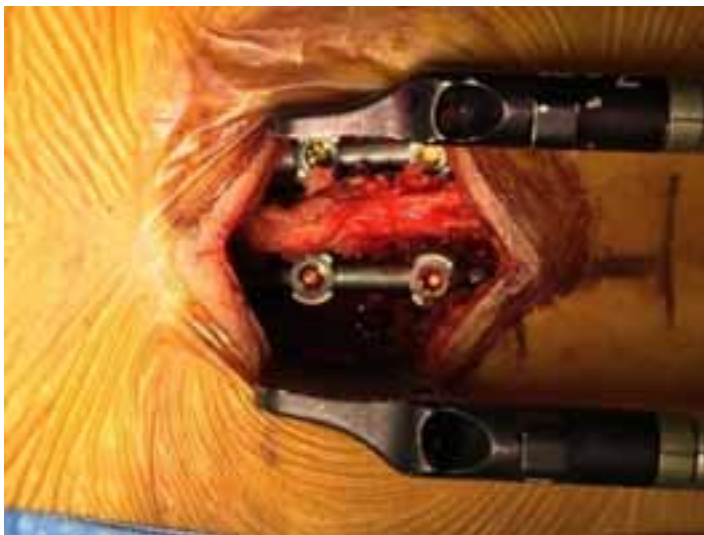
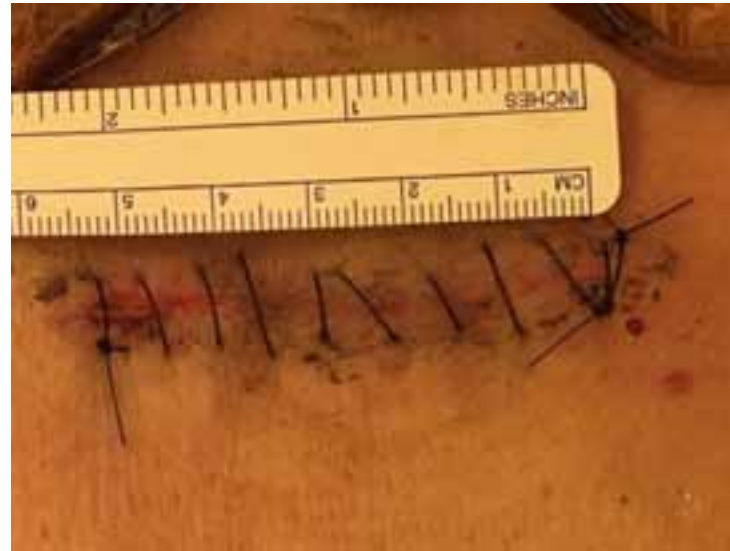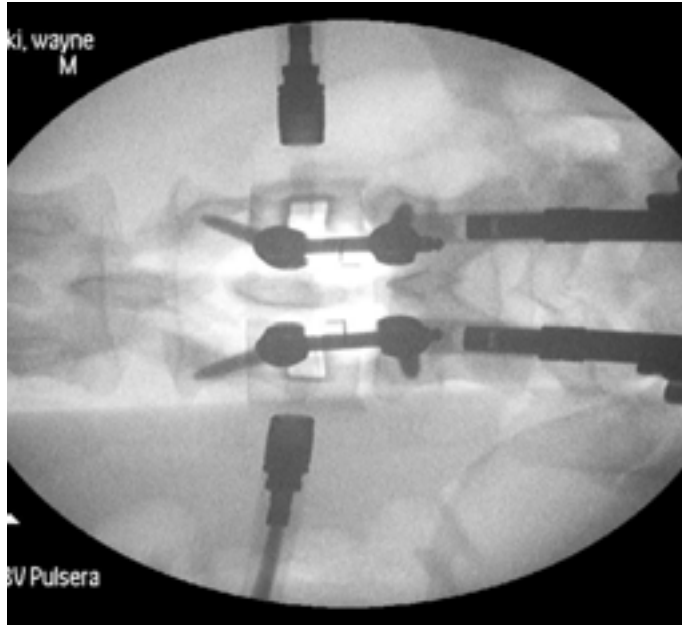
Eigr Surgical  
Illumination System  
121000




# MIDLF: Surgery



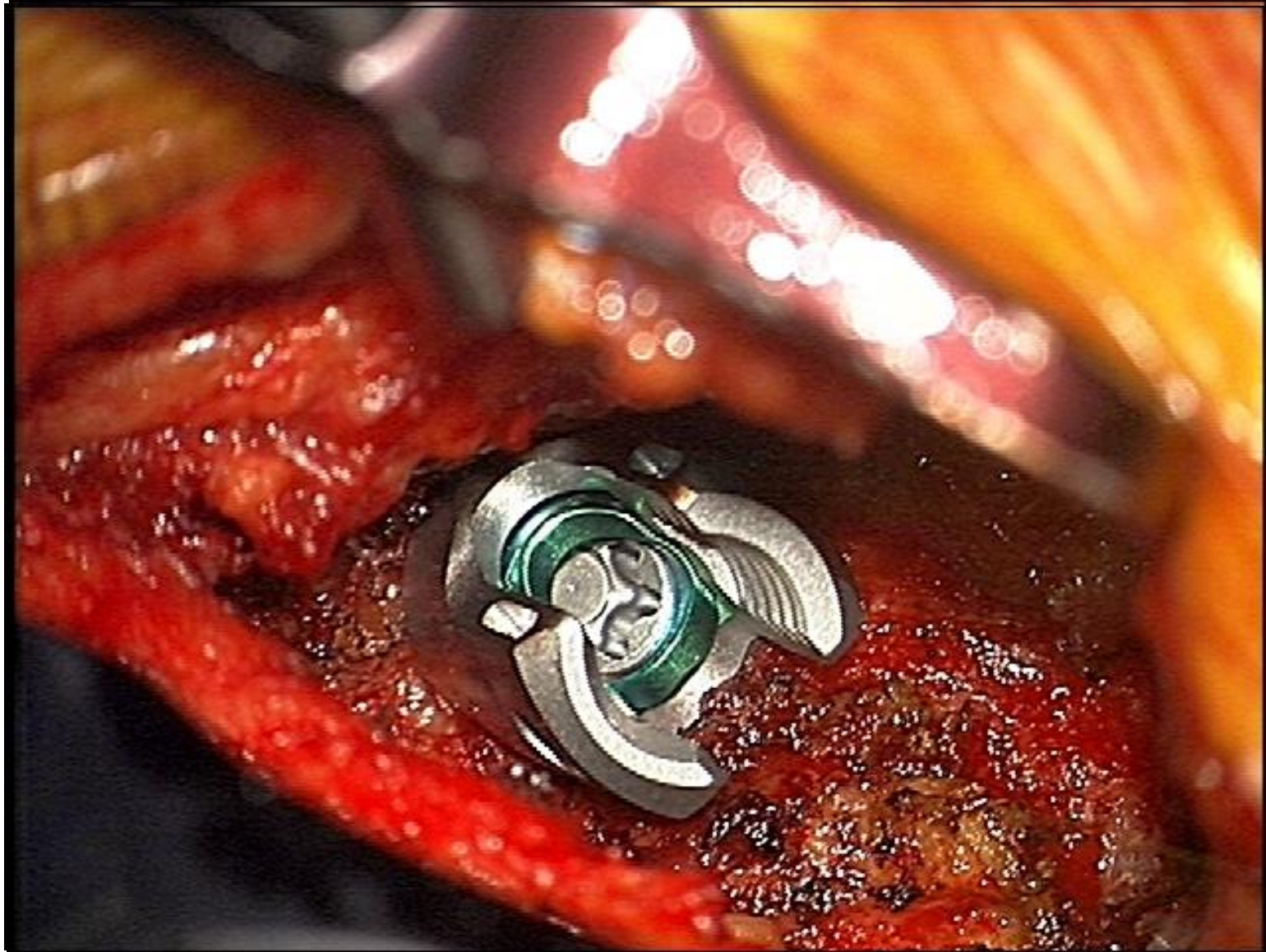
# MIDLF Surgery



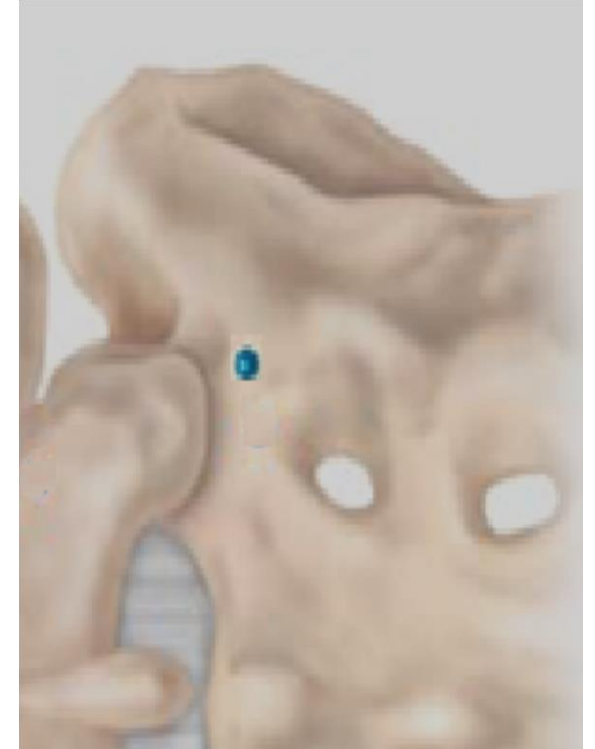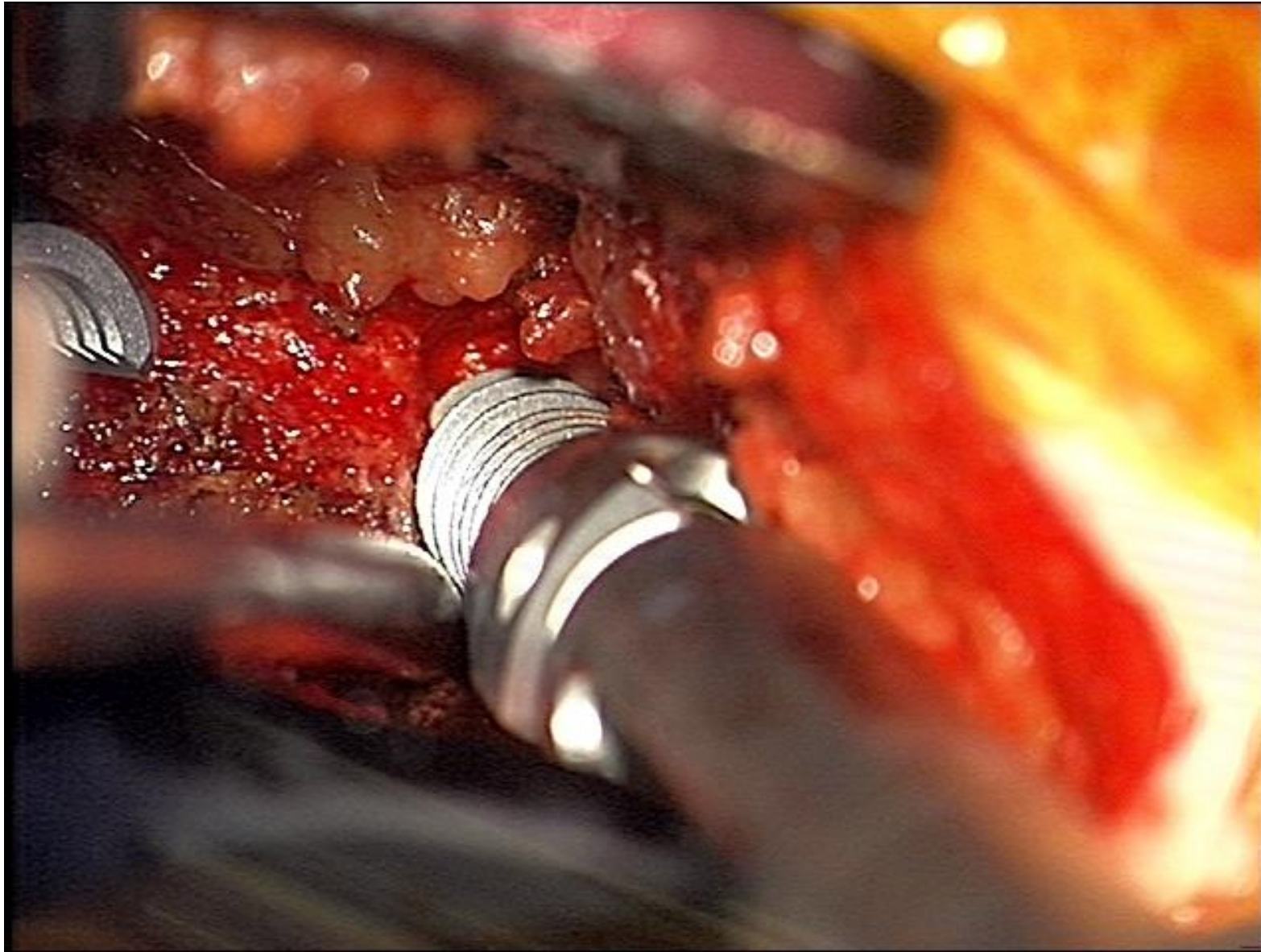
# MIDLF (L5-S1)



# MIDLF L5-S1 (R L5)

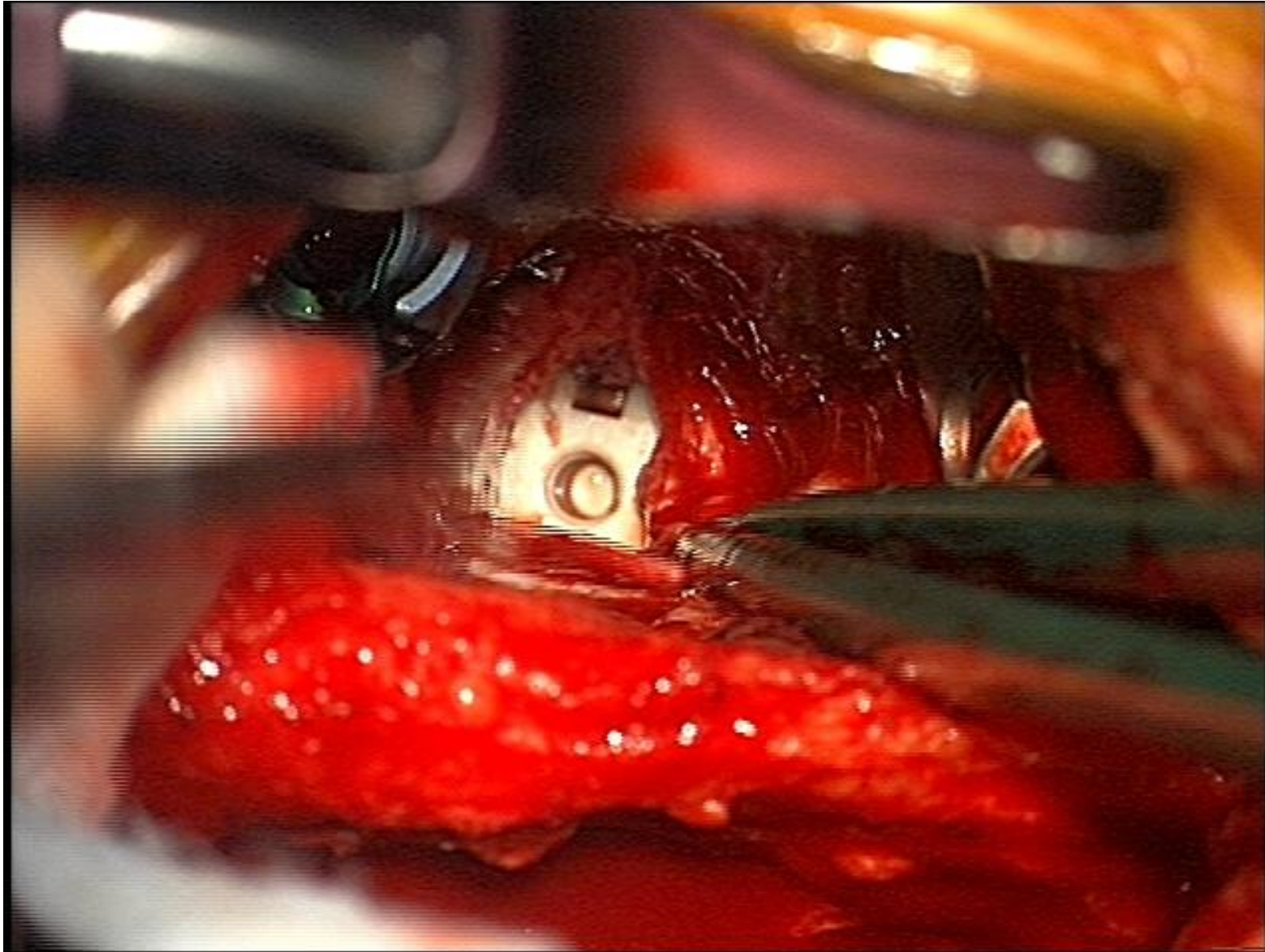


# MIDLIF L5-S1 (R S1)

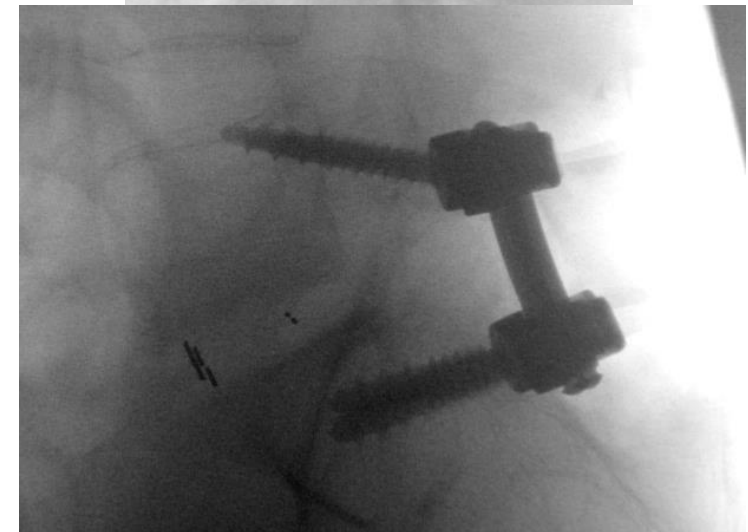
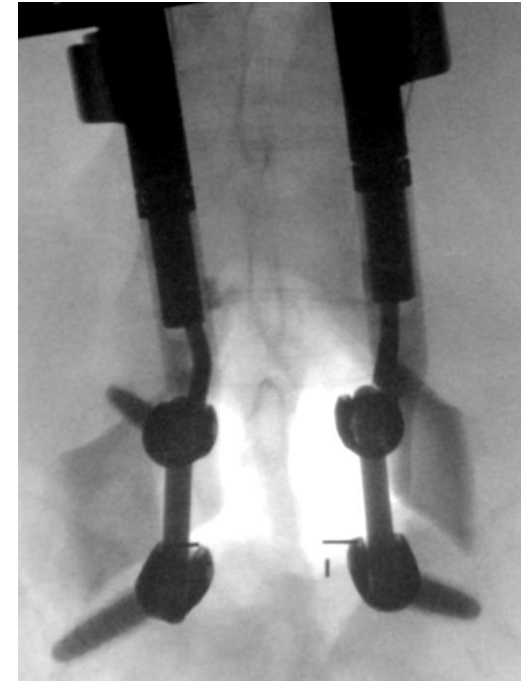
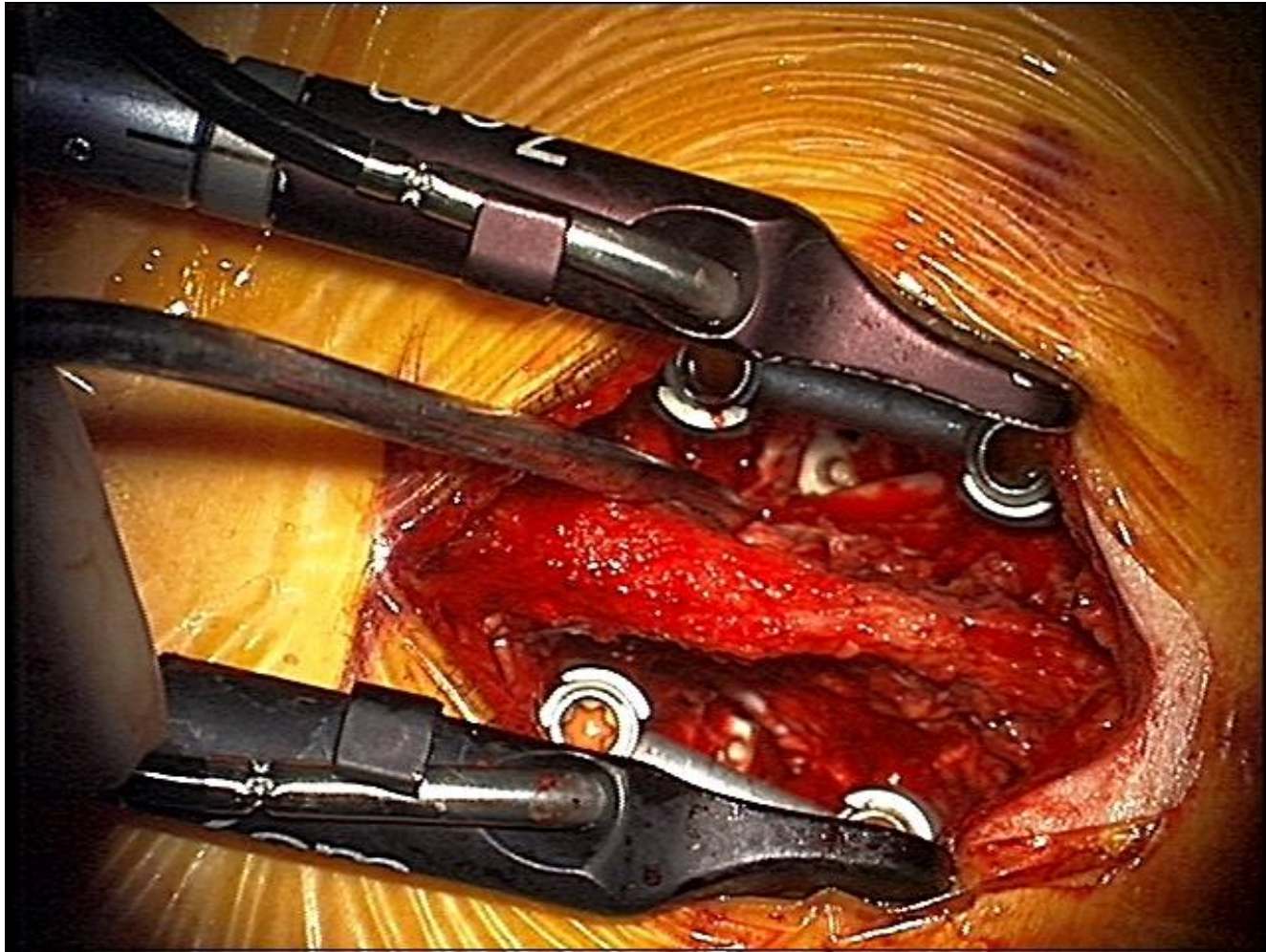




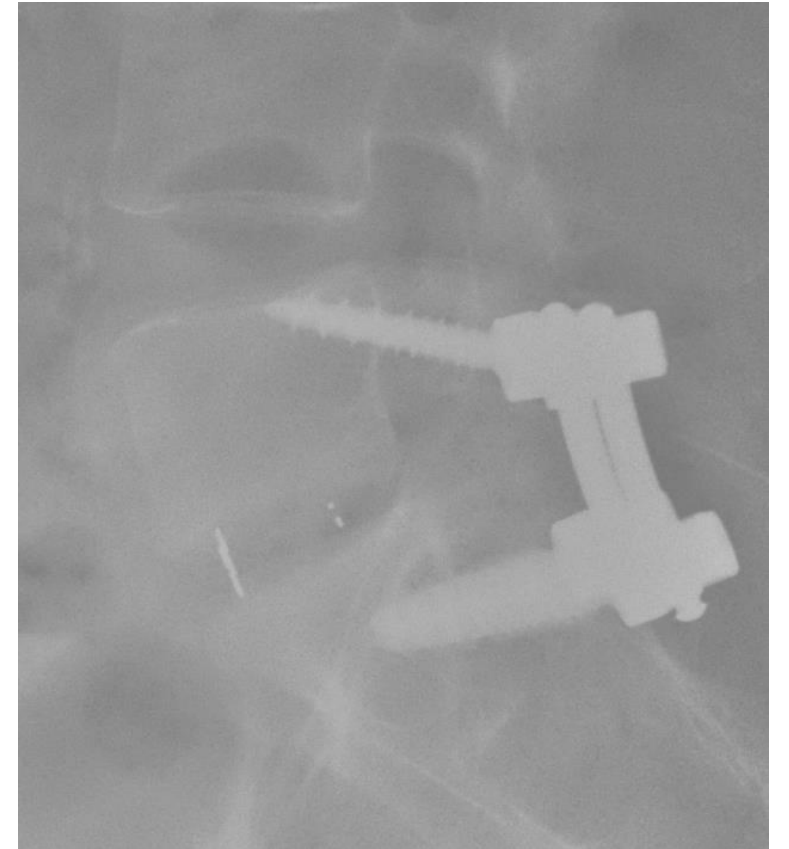
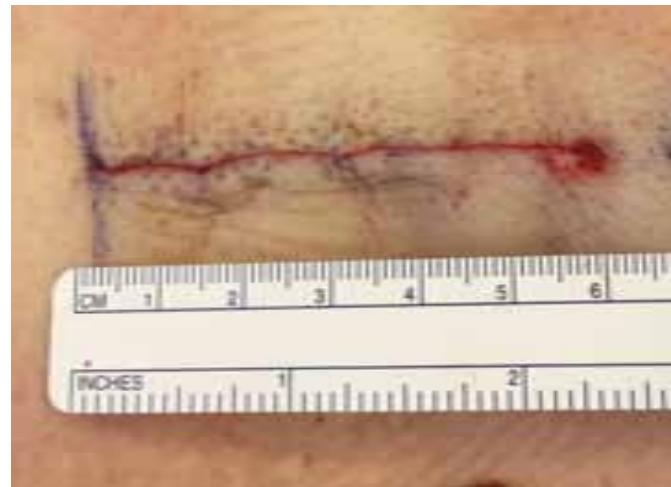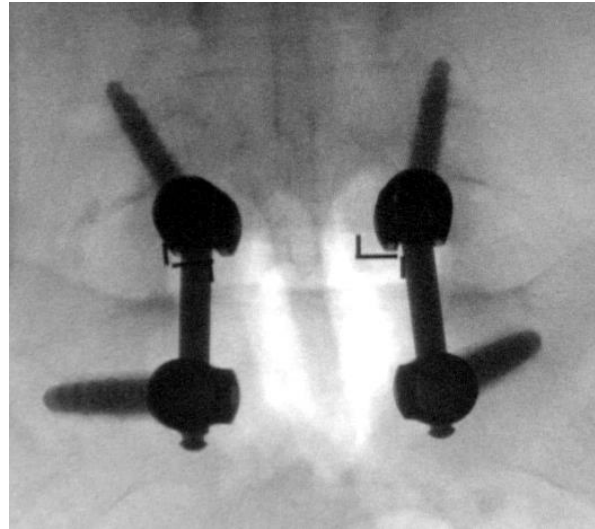
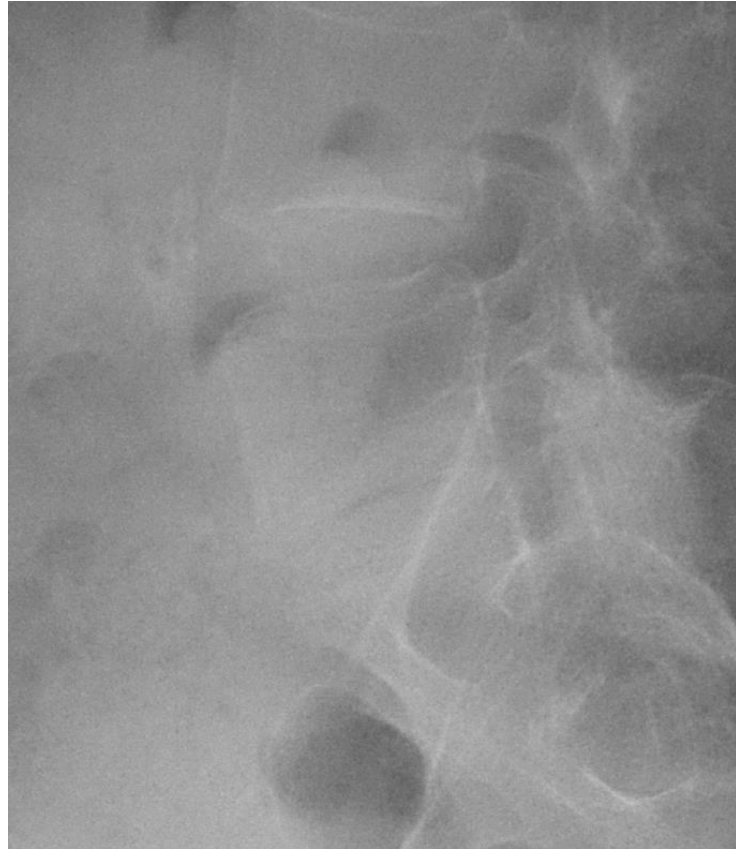# MIDLIF (L5-S1) R PLIF



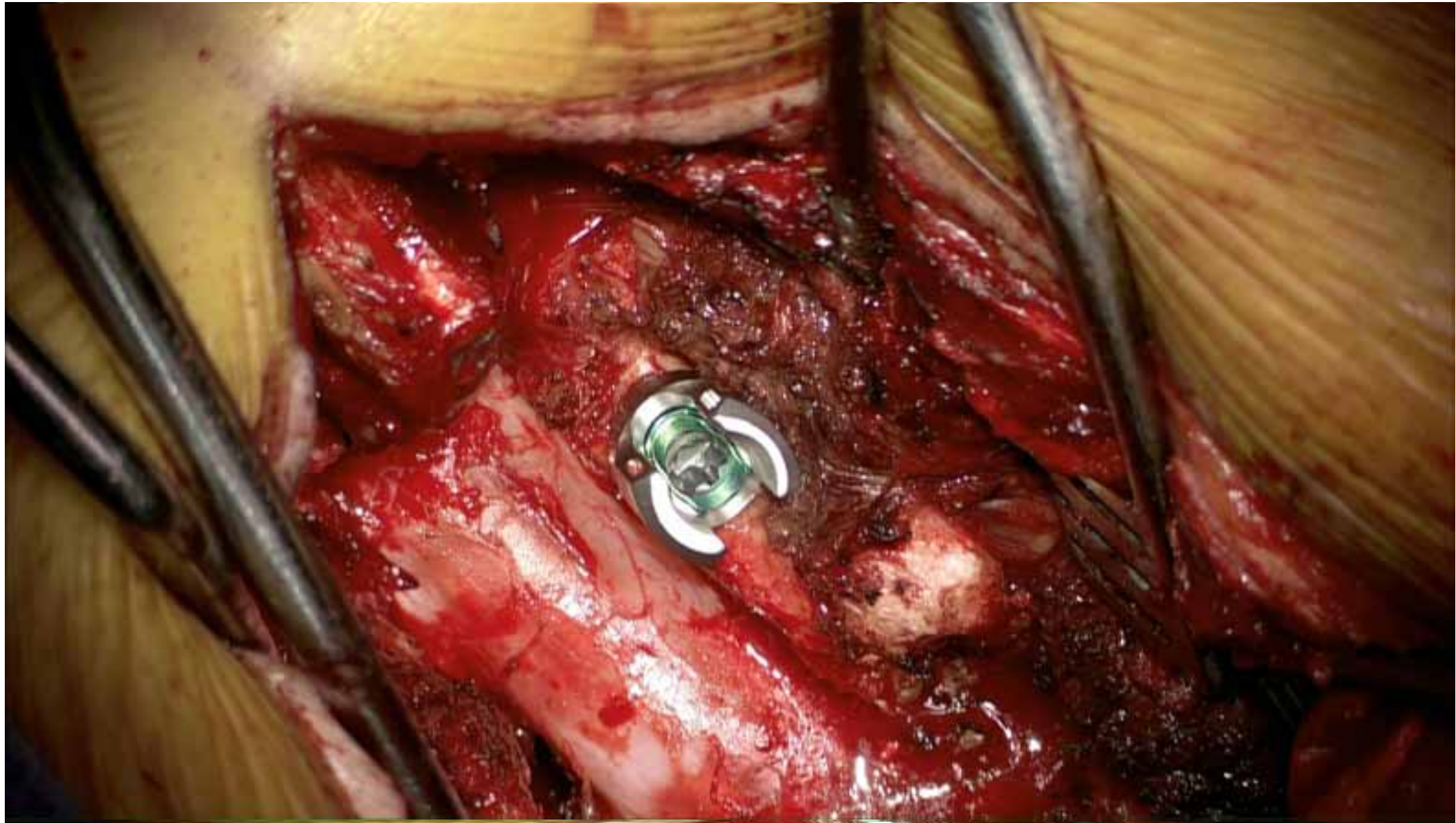
# MIDLF (L5-S1)



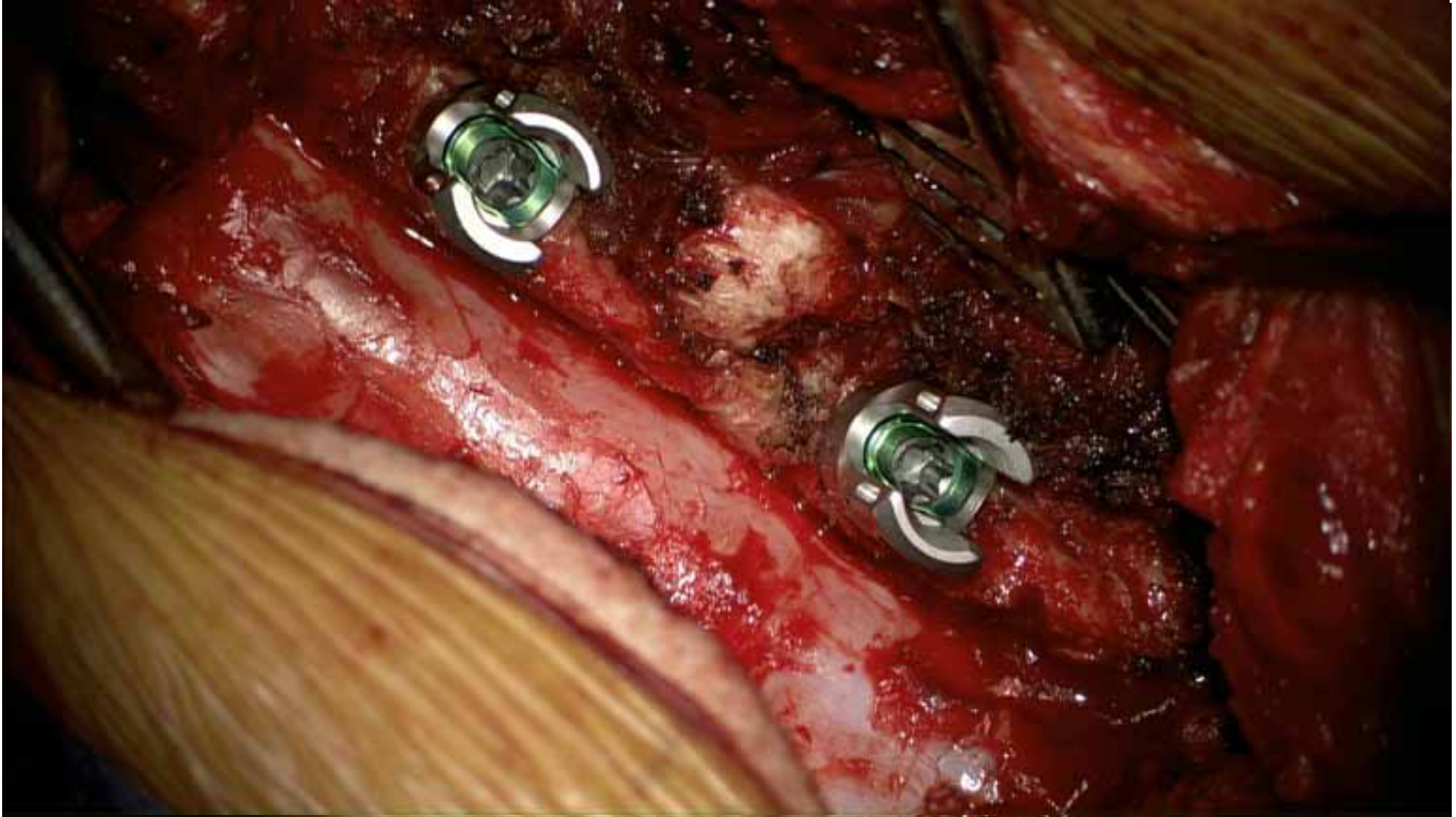# MIDLF (L5-S1)



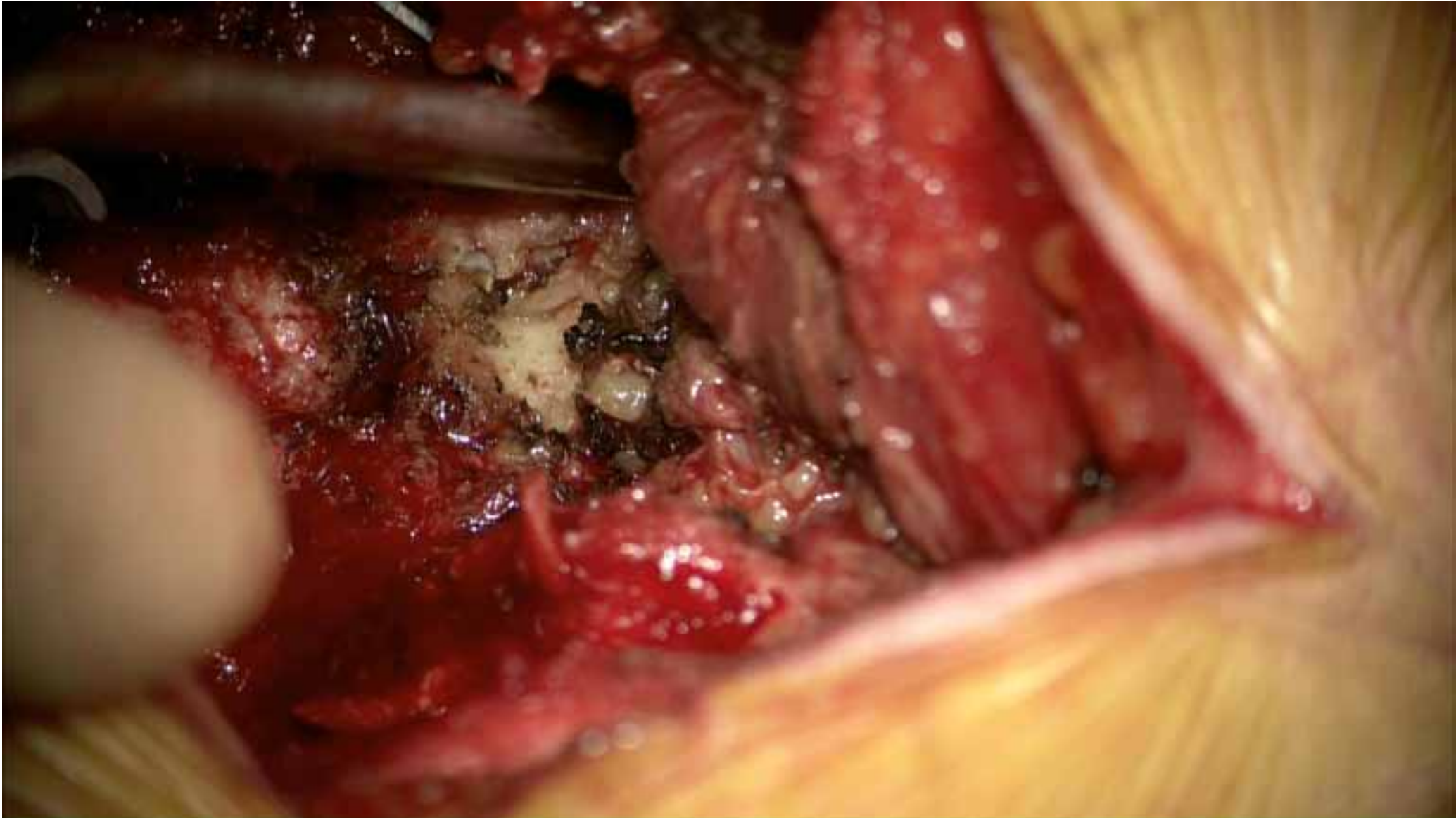# Operative Technique ( R L3)



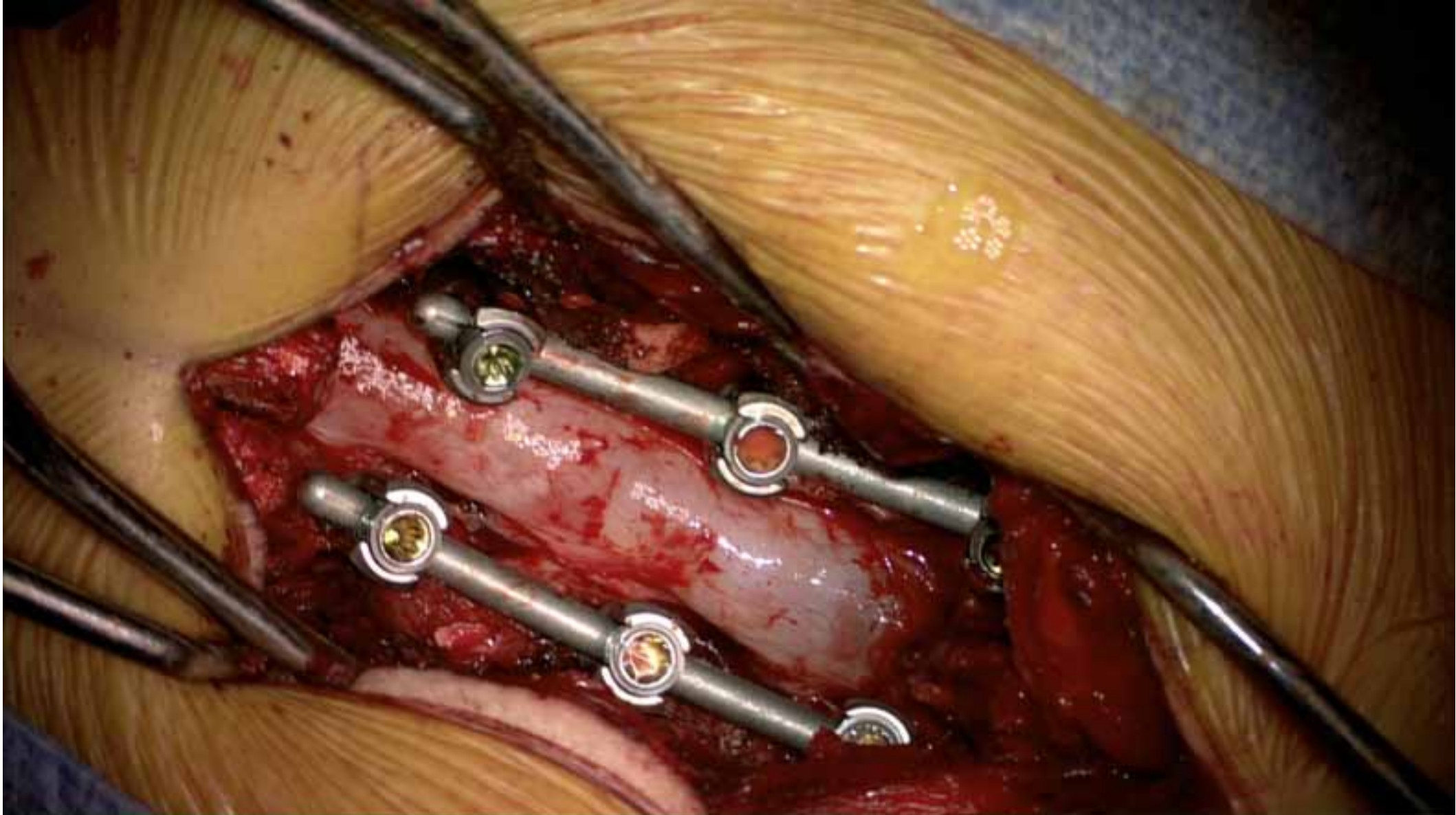
# Operative Technique (R L4)



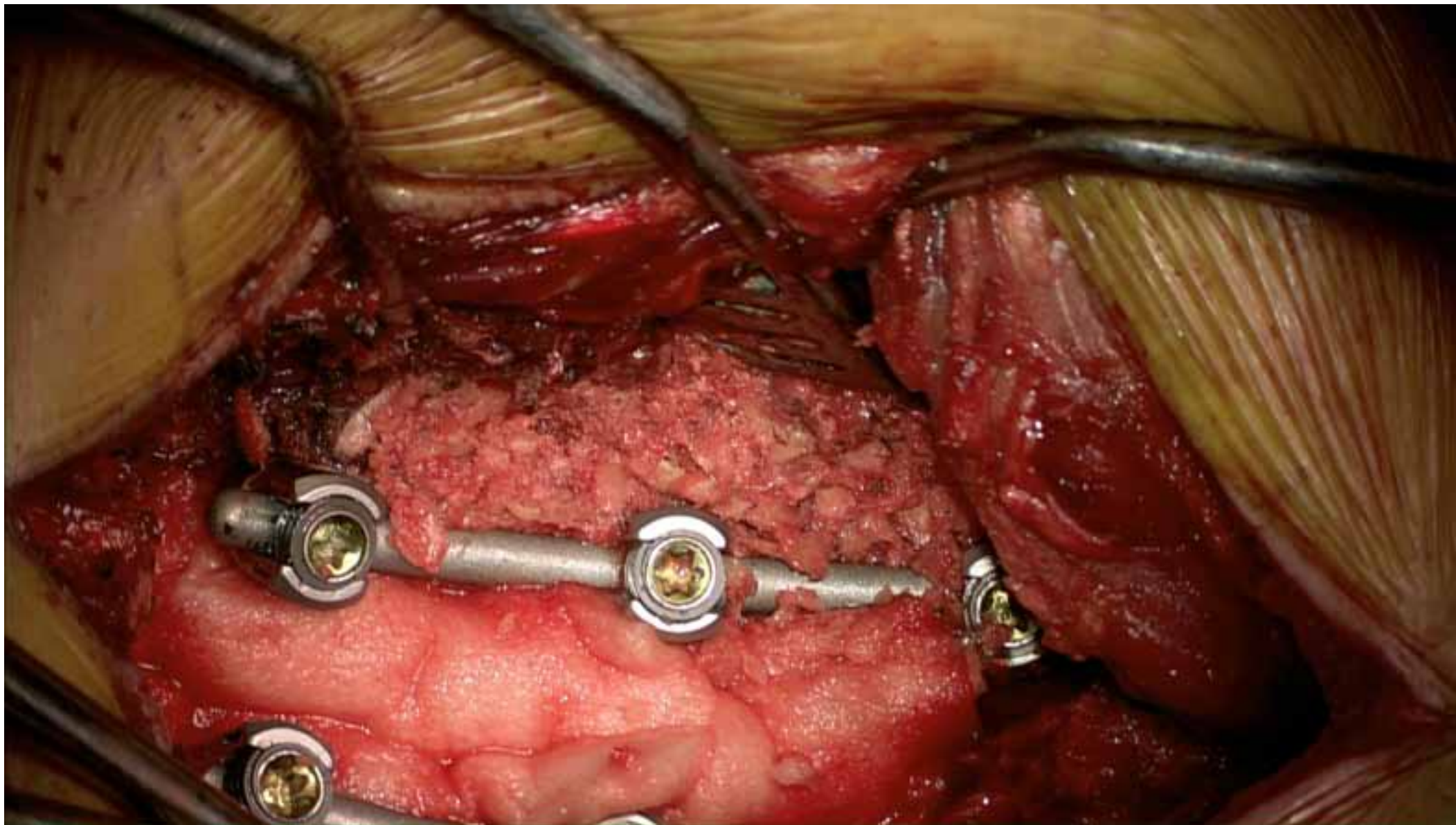
# Operative Technique (R L5)



# Operative Technique (Screw/Rod)



# Operative Technique (PL Fusion后外侧融合)





# Clinical Applications of MidLF/Cortical Screws

MIS alternative to MIS-TLIF  
新的微创选择

- More reliable Bilateral decompression esp. for foramen 双侧减压更方便
- Easier to perform in Multi-level decompression 多节段减压更容易
- Allows PLIF for better elevation of disc height and less graft subsidence (Spondylolisthesis; Osteoporosis; Collapsed disc) 能配合使用PLIF，提供更多自体骨并有效减少融合器沉降

Quality of Bone is less important  
骨质要求低

- Osteoporosis 骨松

Easy Insertion and Line up  
易于植入并对线

- Scoliosis 侧弯
- Hyperlordosis 过度前凸

May Insert next to pedicle screw  
可在椎弓根螺钉旁植入

- Adjacent Level Disease 邻椎病

Medial Screw allowing Large Surface area for bone grafting  
更大的植骨空间

- Pseudoarthrosis 假关节

# MidLF vs. MIS-TLIF: Non-inferiority Results

## 非劣性研究

### Medialized, Muscle-Splitting Approach for Posterior Lumbar Interbody Fusion

Technique and Multicenter Perioperative Results

Yasu Kikawa, MD,\* Goroichi Doi, MD,\* Gregory Puffer, MD,<sup>†</sup> and Arind Aluja, MD<sup>‡</sup>

**TABLE 3. Complications Following MAS PLIF**

	n = 138
Intraoperative—n (%)	
Dural tear	5 (3.6)
Perioperative—n (%)	
Pulmonary embolism	2 (1.4)
Deep vein thrombosis	1 (0.7)
Urinary retention	1 (0.7)
Urinary tract infection	1 (0.7)
Wound infection	2 (1.4)
L5 fracture with implant subsidence	1 (0.7)
Six months postoperative—n (%)	
Persistent pain, possible prolonged union	1 (0.7)

n indicates number of patients.

**Low Complication Rate**  
**更低的并发症发生率**

### Short-Term Results of Transforaminal Lumbar Interbody Fusion Using Pedicle Screw with Cortical Bone Trajectory Compared with Conventional Trajectory

Yul Kangwon, Naehwa Myeokshi, Michio Hongo, Yoshimasa Ishikawa, Daisho Kudo, Yusaku Shimada

Department of Orthopedic Surgery, Aichi University Graduate School of Medicine, Aichi, Japan

26 divided into three groups: TLIF with pedicle screw insertion by conventional minimally invasive methods via the Wiltse approach (M-TLIF, n=10), TLIF with percutaneous pedicle screw insertion (P-TLIF, n=6), and TLIF with pedicle screw insertion with CBT (CBT-TLIF, n=10).

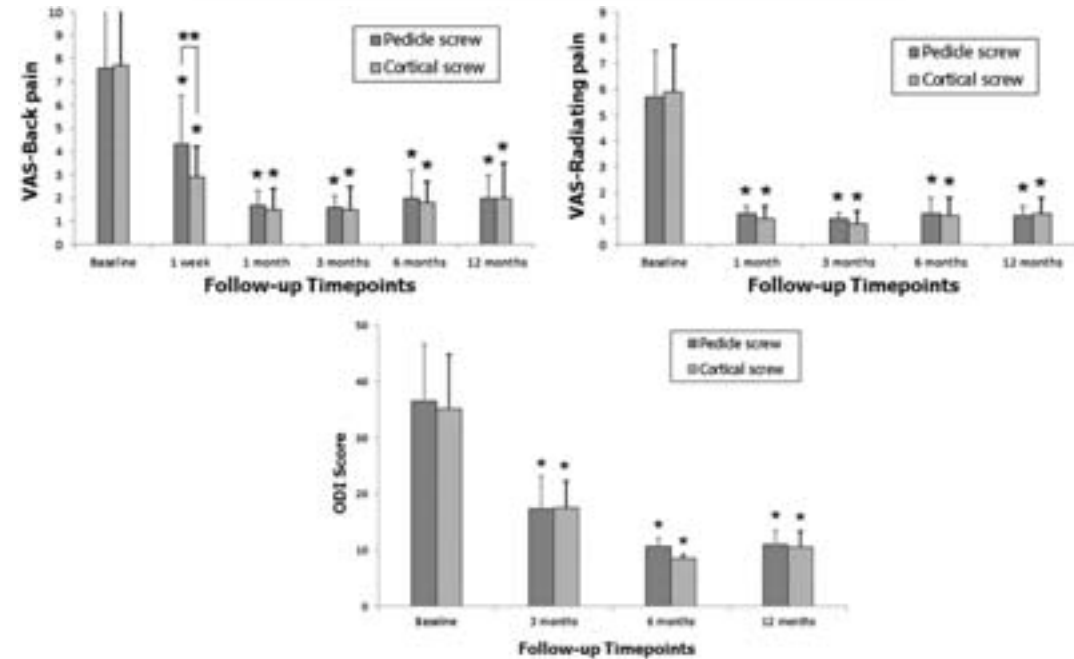
**Conclusions:** CBT-TLIF resulted in less blood loss and a **shorter operative duration than M-TLIF or P-TLIF. Postoperative rates of bone union, maintenance of lordotic angles, and accuracy of pedicle screw positions were similar among the three groups.**

CBT螺钉手术时间更短，术后融合率，恢复前凸角，以及置钉准确率无显著差异

### The comparison of pedicle screw and cortical screw in posterior lumbar interbody fusion: a prospective randomized noninferiority trial

Gan Woo Lee, MD<sup>\*,†</sup>, Jung-Hwan Seo, MD<sup>\*,†</sup>, Myun-Whan Ahn, MD<sup>\*,†</sup>, Ho-Joong Kim, MD<sup>\*,†</sup>, Jin S. Yoon, MD<sup>\*,†</sup>

<sup>\*</sup>Department of Orthopedic Surgery, Seoul National University Hospital, Daehak-ro 51, Gwanak-gu, Seoul 151-747, Republic of Korea; <sup>†</sup>Department of Orthopedic Surgery, Seoul National University Hospital, 152 Daehak-ro, Gwanak-gu, Seoul, Republic of Korea; <sup>‡</sup>Spine Center and Department of Orthopedic Surgery, Samsung University Hospital, 178 Ilgong-ro, Songnam, Seoul, Republic of Korea; <sup>§</sup>Spine Center and Department of Orthopedic Surgery, Seoul National University College of Medicine and Seoul National University Research Hospital, 57 Gongsu-ro, Gwanak-gu, Seoul 151-747, Republic of Korea



**Conclusion:** CS in PLIF provides similar clinical and radiologic outcomes compared to PS in PLIF. On the basis of the present study, we suggest CS to be a reasonable alternative to PS in PLIF.

# Alternative to TLIF: Bilateral Decompression

## 双侧减压

MIS through farnial approach as alternative to MIS-TLIF

- **Bilateral decompression esp. for foramen**
- Multi-level decompression
- When Better Lordosis is needed (esp. Spondylolisthesis)

Quality of Bone not as important

- Osteoporosis

Easy Insertion and Line up nice

- Scoliosis
- Hyperlordosis

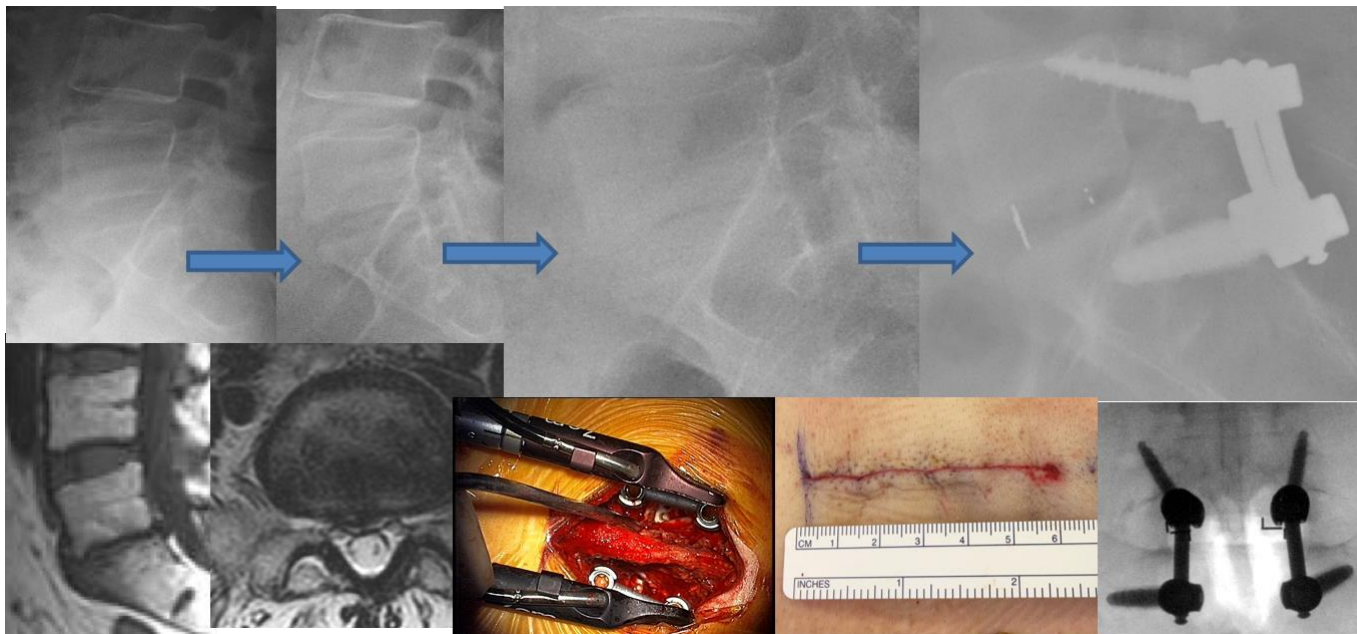
May Insert at level of pedicle screw

- Adjacent Level Disease

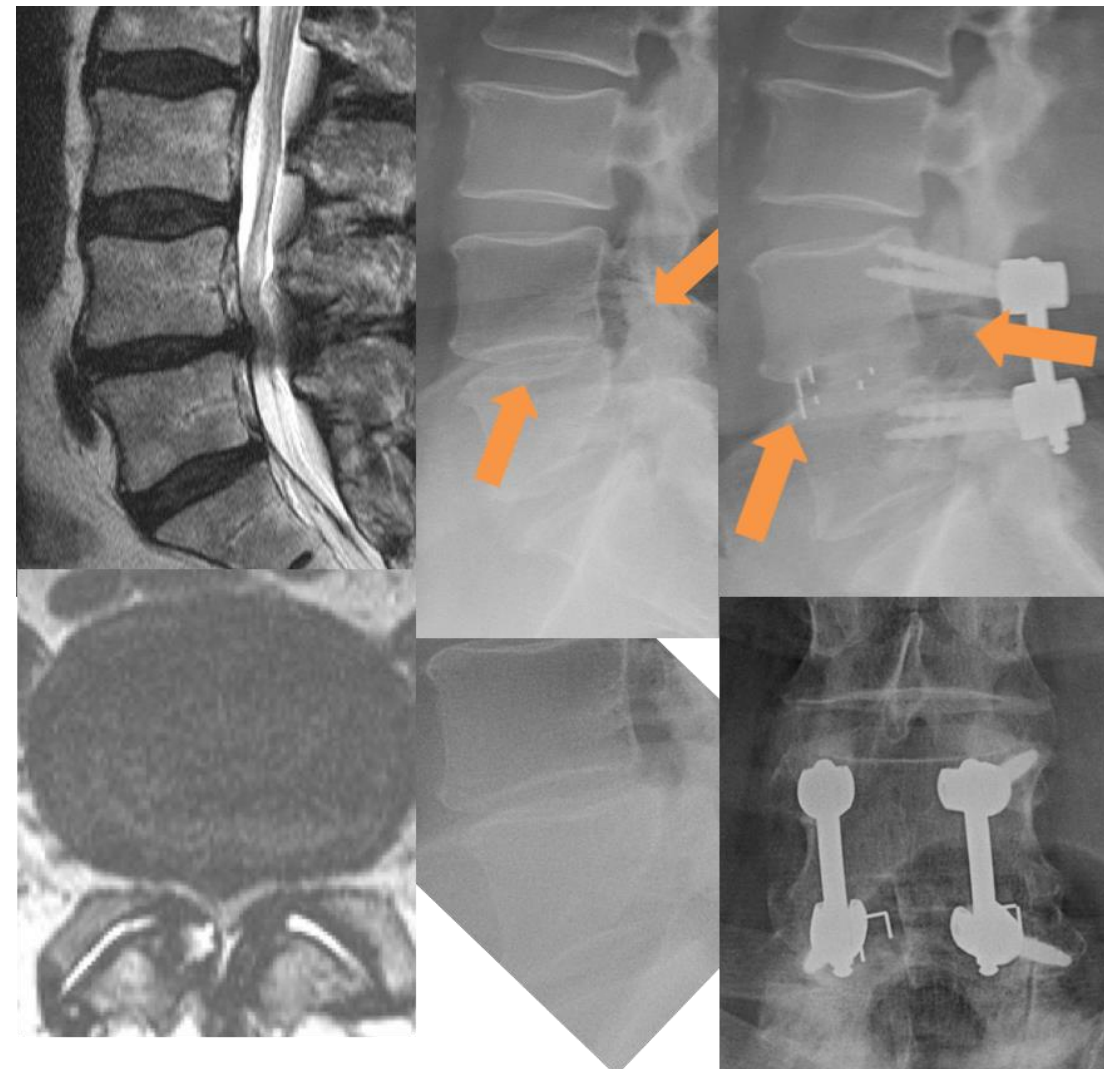
Medial Screw allowing Large Surface for bone grafting

- Pseudoarthrosis

Allows **Sequential** Distraction with foraminal decompression

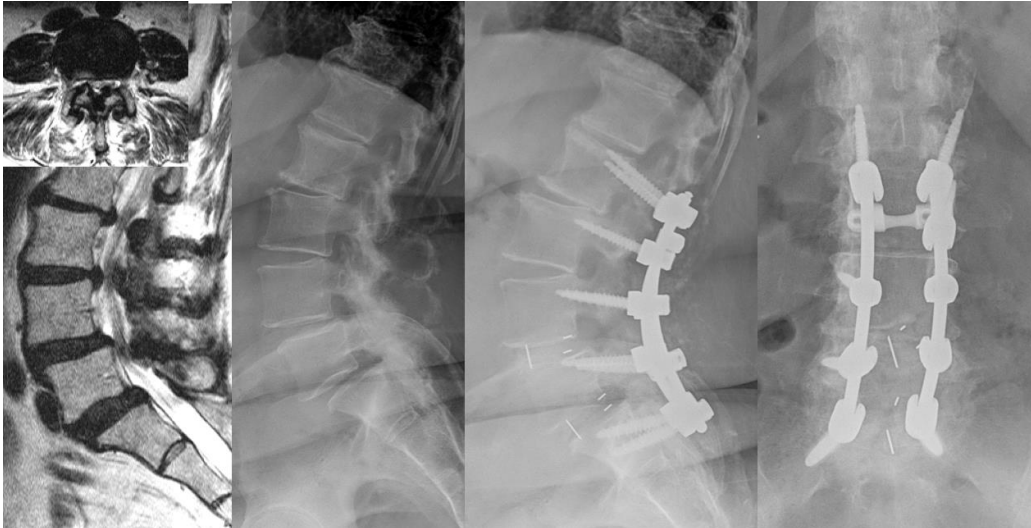
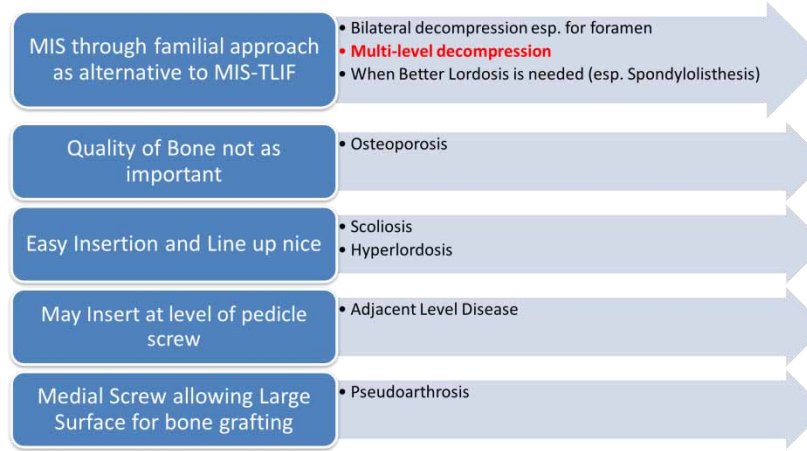


Direct **Bilateral** central and foraminal decompression



# Alternative to TLIF: Mutli-Level Decompression

## 多节段减压



- ✓ Easier surgery than MIS-TLIF 更简单易学
- ✓ Less invasive than conventional open 较常规开放手术窗口减少

# Alternative to TLIF: Spondylolisthesis

- MIS through familial approach as alternative to MIS-TLIF
  - Bilateral decompression esp. for foramen
  - Multi-level decompression
  - When Better Lordosis is needed (esp. Spondylolisthesis)
- Quality of Bone not as important
  - Osteoporosis
- Easy Insertion and Line up nice
  - Scoliosis
  - Hyperlordosis
- May Insert at level of pedicle screw
  - Adjacent Level Disease
- Medial Screw allowing Large Surface for bone grafting
  - Pseudoarthrosis

## Clinical Comparison of Two MIS Fusion Techniques for Lumbar Spondylolysis and Isthmic Spondylolisthesis

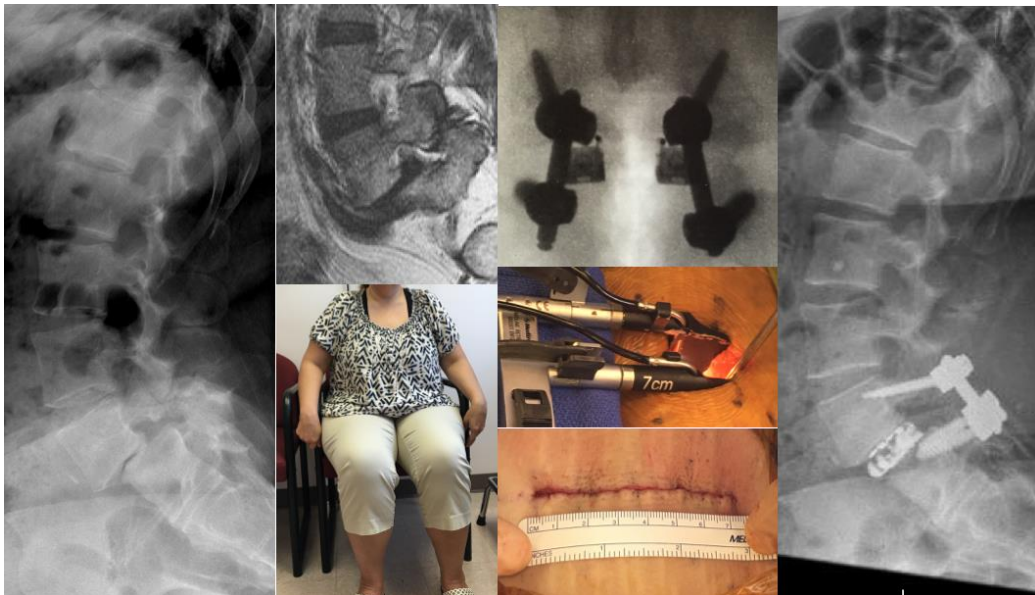
Presented at SMISS Annual Forum 2018  
 By Ryo Fujita MD  
 With Yoshihisa Kotani MD, PhD

## Clinical & Radiological Comparison Between Three Different Minimally Invasive Surgical Fusion Techniques for Single-Level Lumbar Spondylolisthesis: MIS-PLF vs MIS-TLIF vs MIDLF

Presented at SMISS Annual Forum 2018  
 By Mohamed Elmekaty MD  
 With Yoshihisa Kotani MD, PhD, Esmad Elmehy MD, PhD, Ivan Guechar MD

Results: **MIDLF showed a better effective rate in terms of low back pain and invasiveness with significantly lower CK (327 vs 1001) and CRP (1.3 vs 2.1) on POD1.** 术后1天，MIDLF术式病患的腰背痛减缓明显，抗体血清和C反应蛋白指数也较低

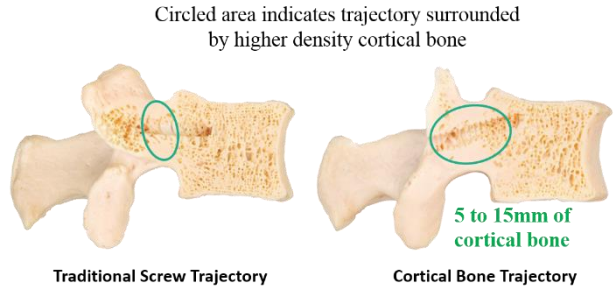
Conclusions: **MIDLF demonstrated higher fusion rate, less screw loosening rate, and less invasiveness and was more effective in maintaining correction, restoring LL angle, segmental disc angle and disc height,** which was attributed to high fixation strength of modified CBT screws. 使用MIDLF技术，术后融合率高，螺钉松动率低，切口减小，在保持术后矫正，恢复腰椎前凸，间盘高度等方面都有着优异表现



# Cortical vs Pedicle screw Strength in Age/Osteoporosis

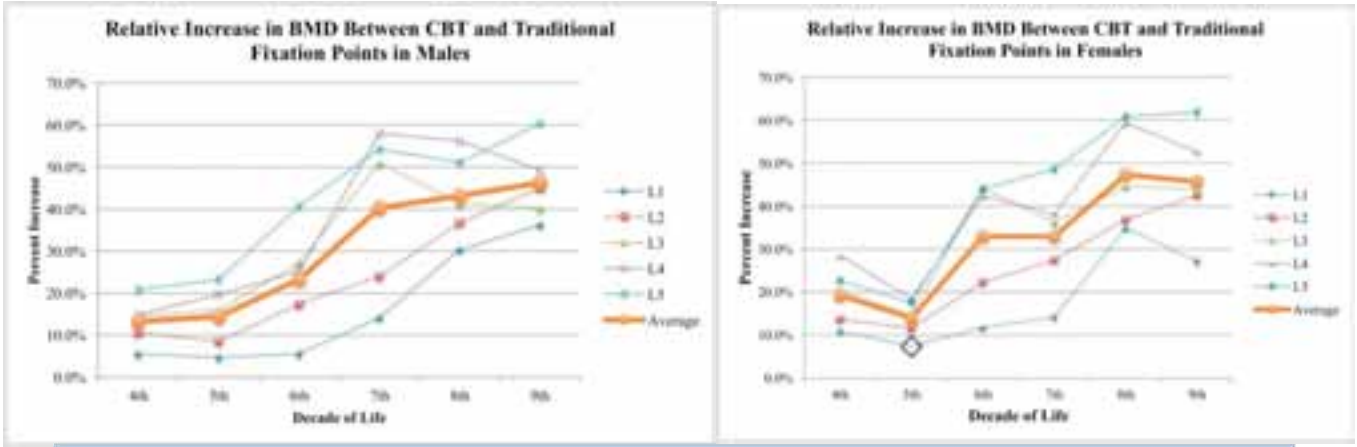
## 在年长及骨质疏松患者上的表现对比

- MIS through minimal approach as alternative to MIS-TLIF
  - Bilateral decompression esp. for foramen
  - Multi-level decompression
  - When Better Lordosis is needed (esp. Spondylolisthesis)
- Quality of Bone not as important
  - Osteoporosis
- Easy Insertion and Line up nice
  - Scoliosis
  - Hyperlordosis
- May Insert at level of pedicle screw
  - Adjacent Level Disease
- Medial Screw allowing Large Surface for bone grafting
  - Pseudoarthrosis



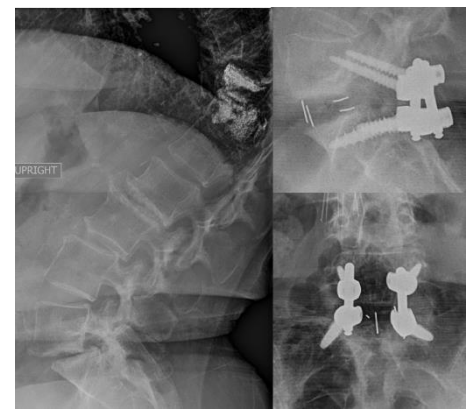
Santoni BG, et al. Cortical bone trajectory for lumbar pedicle screws. Spine J. 2008 Sep 12.

The Spine Journal 2016 16, 835-841



Relative increase in BMD at the CBT versus traditional pedicle screw fixation points in osteoporotic patients and age-gender matched controls

	L1	L2	L3	L4	L5	Average increase in BMD
Osteoporotic	54.6%	74.5%	68.1%	73.6%	96.4%	73.4%
Control	4.6%	14.2%	24.7%	27.3%	33.3%	20.8%
p-Value	.011**	.048**	.011**	.006**	<.001**	.008**



**SMISS**  
Society for Minimally Invasive Spine Surgery

HOME ABOUT EDUCATION SEARCH ABSTRACTS MEETINGS MEMBERSHIP

**Clinical Comparison of Two Spinal Reconstruction Techniques for Osteoporotic Vertebral Collapse: Conventional Pedicle Screw vs Modified CBT Screw**

Presented at 2015 Annual Meeting  
By Roy Fujita MD  
Wm. Yusef Hattar MD, PhD

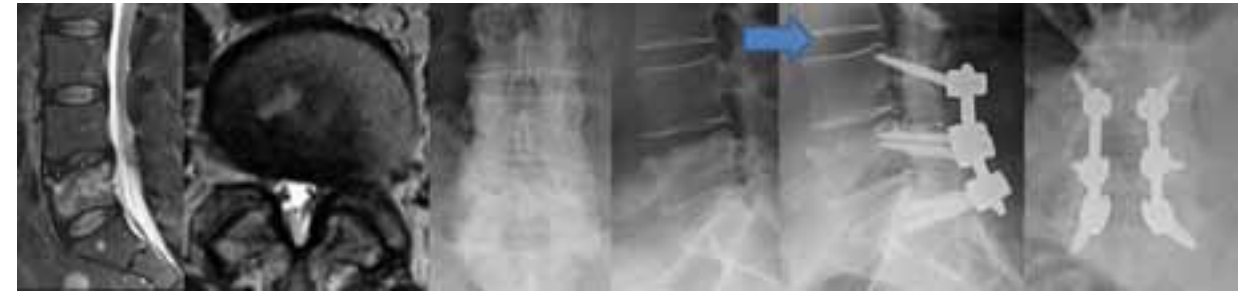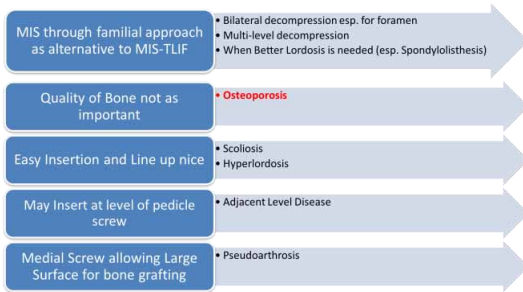
**Conclusions: mCBT showed a significantly less loss of correction, demonstrating the advantage of mCBT over PS.**

Bone mineral density around CBT screw is significantly greater than that of the traditional pedicle screw. This difference is even more pronounced when comparing osteoporotic and elderly patients to the general population. 由于皮质骨螺钉钉道周围被高密度的骨皮质包绕，所以在骨松、年长等骨质较差的患者上应用表现更优异

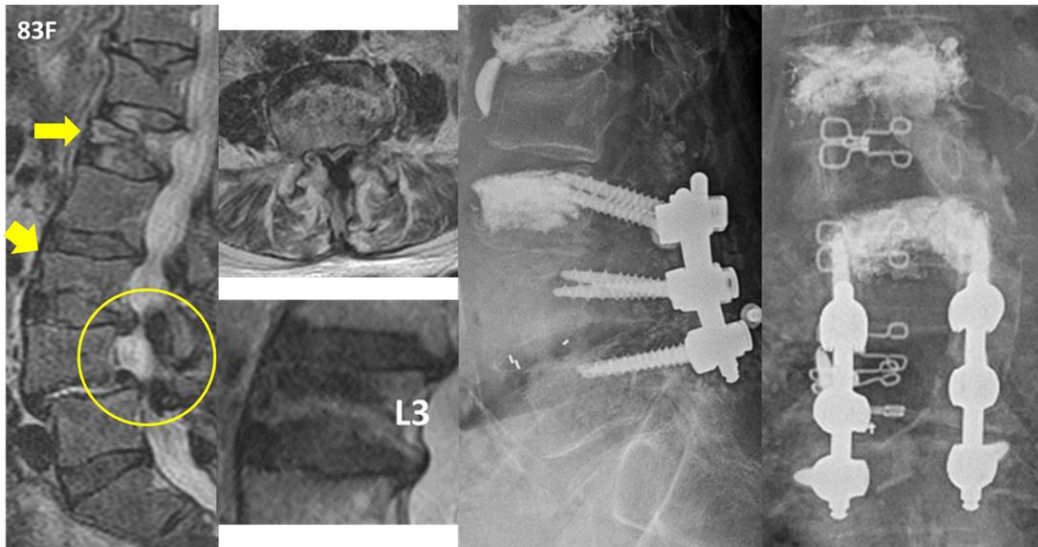
# Value in Osteoporotic Fx

## 1. When Decompression is needed 当需要减压时

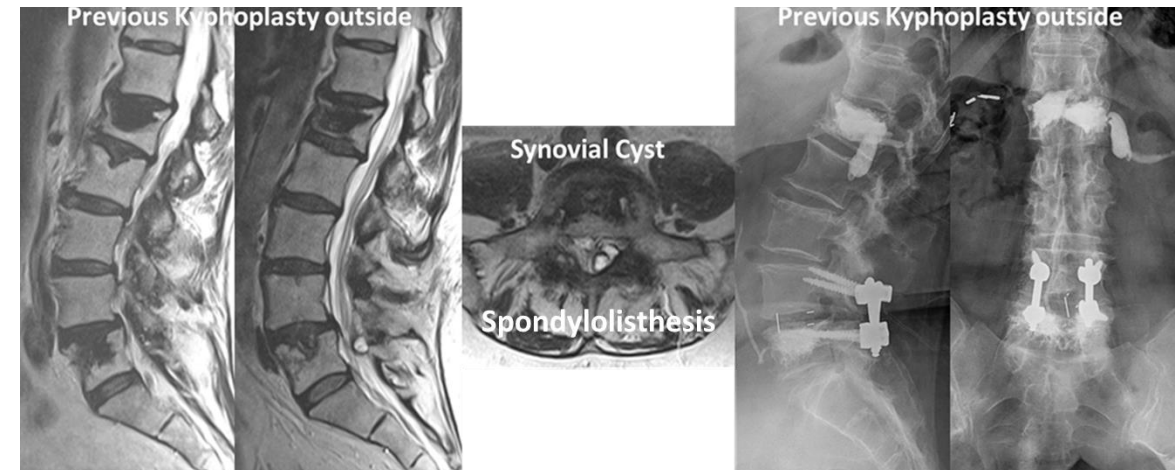
Allows shorter segment fixation by fixing the fractured vertebra itself 更少的节段固定



## 2. When Shorter Segment Fusion and stability is Desired 当需要短节段融合及即刻稳定时



## 3. When a Screw is to be Implanted in a Previously Cemented Vertebra 当需要在一个先前做过骨水泥椎体成形术的椎体中置钉时



# Easier to Insert: 更易置钉

MIS through faniilar approach as alternative to MIS-TLIF

- Bilateral decompression esp. for foramen
- Multi-level decompression
- When Better Lordosis is needed (esp. Spondylolisthesis)

Quality of Bone not as important

- Osteoporosis

Easy Insertion and Line up nice

- **Scoliosis**
- Hyperlordosis

May Insert at level of pedicle screw

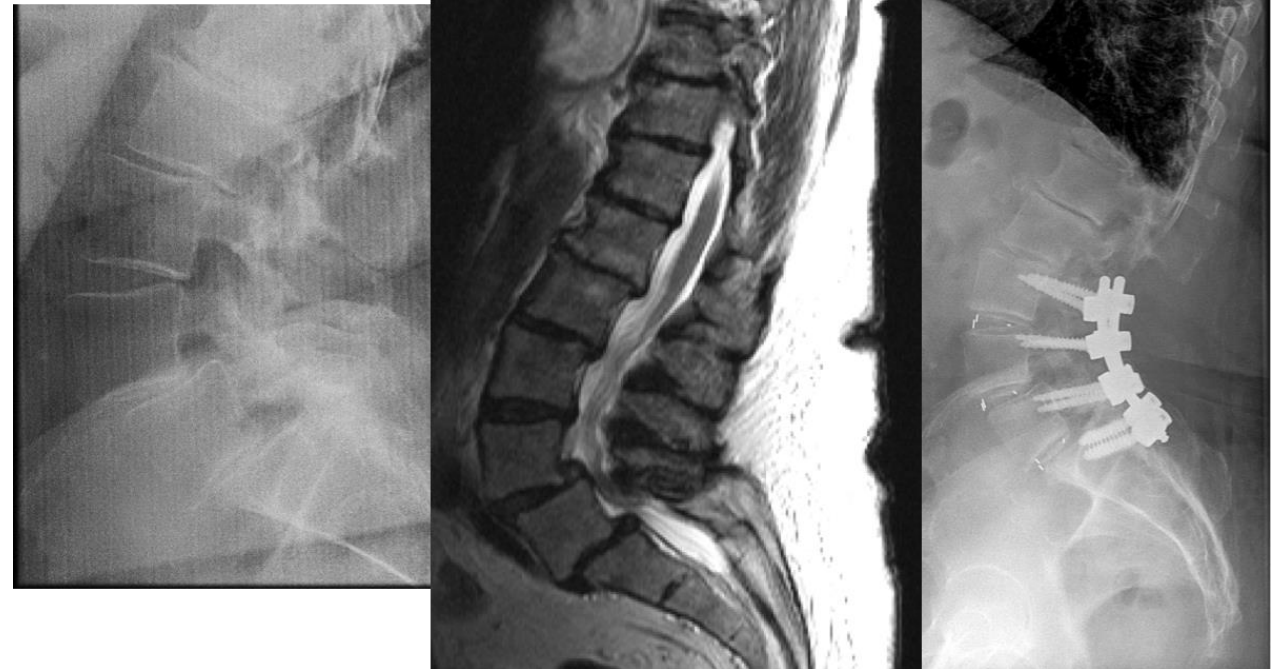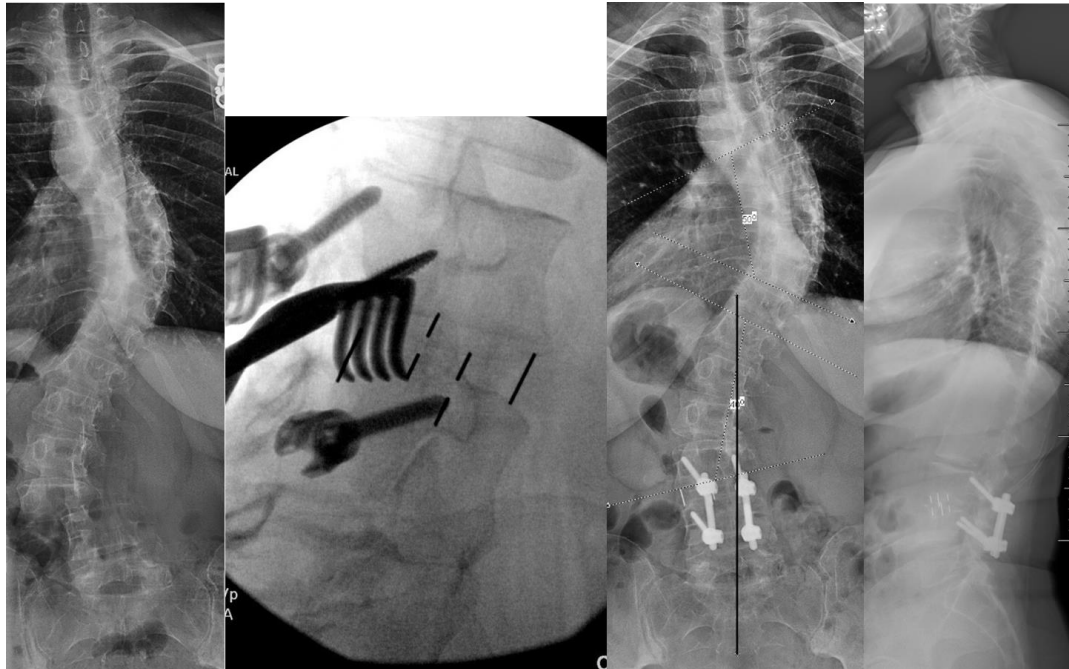
- Adjacent Level Disease

Medial Screw allowing Large Surface for bone grafting

- Pseudoarthrosis

+ hyperlordosis 过度前凸

Scoliosis 侧弯





# Adjacent Level Fixation

MIS through minimal approach as alternative to MIS-TLIF

- Bilateral decompression esp. for foramen
- Multi-level decompression
- When Better Lordosis is needed (esp. Spondylolisthesis)

Quality of Bone not as important

- Osteoporosis

Easy Insertion and Line up nice

- Scoliosis
- Hyperlordosis

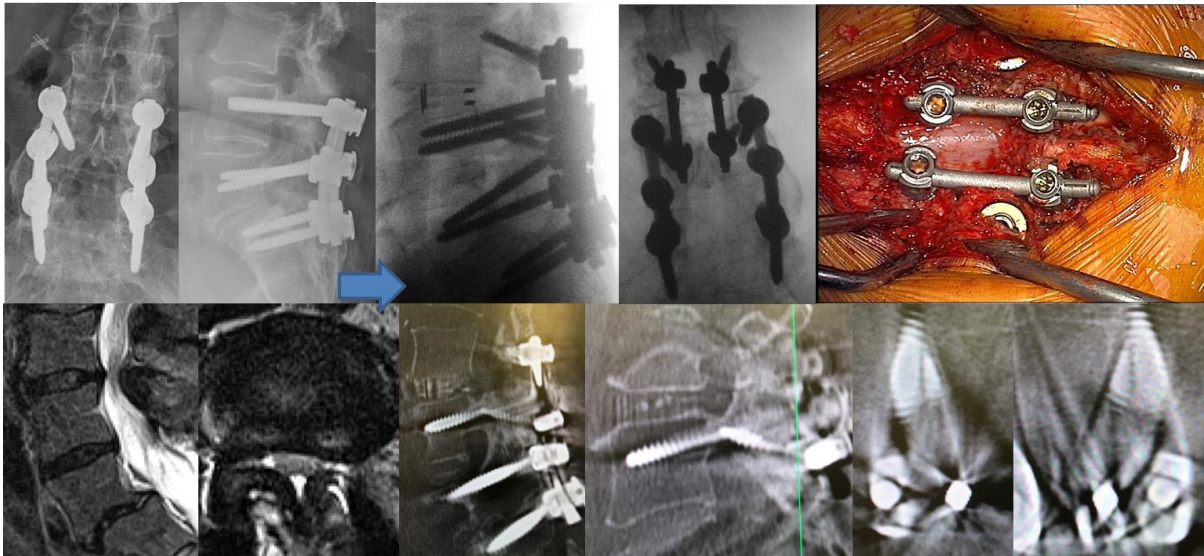
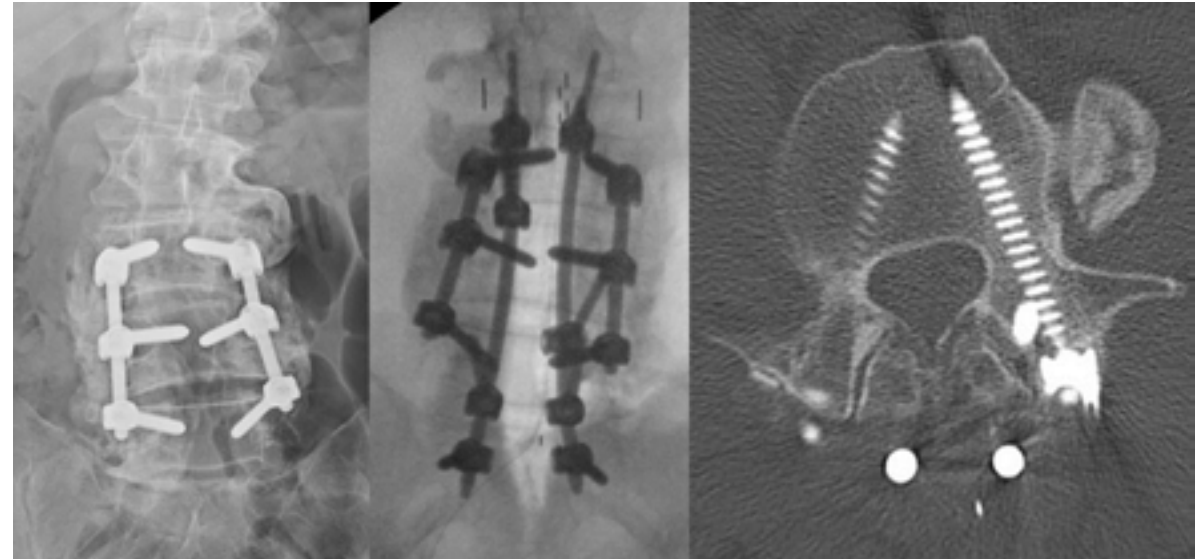
May Insert at level of pedicle screw

- **Adjacent Level Disease**

Medial Screw allowing Large Surface for bone grafting

- Pseudoarthrosis

## Bone-covered Screws 钉道较深的椎弓根螺钉翻修



# Value in ↑ Pseudoarthrosis Risk 减少假关节

MIS through farnal approach as alternative to MIS-TLIF

- Bilateral decompression esp. for foramen
- Multi-level decompression
- When Better Lordosis is needed (esp. Spondylolisthesis)

Quality of Bone not as important

- Osteoporosis

Easy Insertion and Line up nice

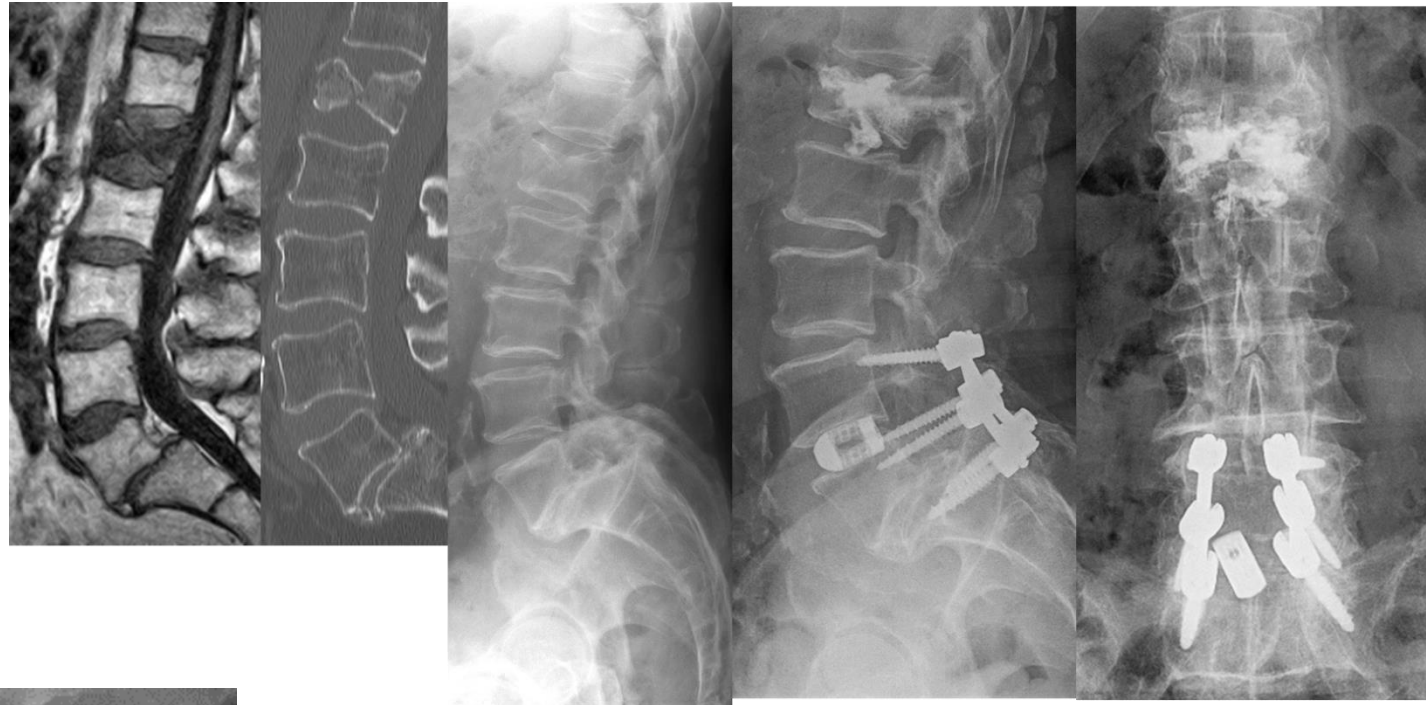
- Scoliosis
- Hyperlordosis

May Insert at level of pedicle screw

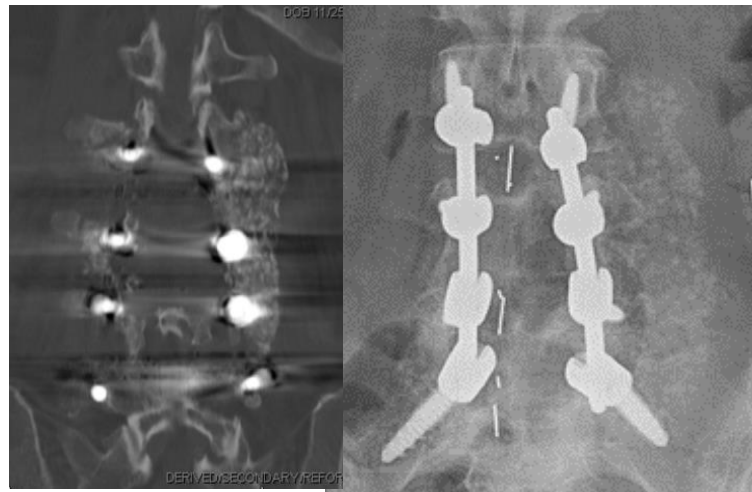
- Adjacent Level Disease

Medial Screw allowing Large Surface for bone grafting

- Pseudoarthrosis

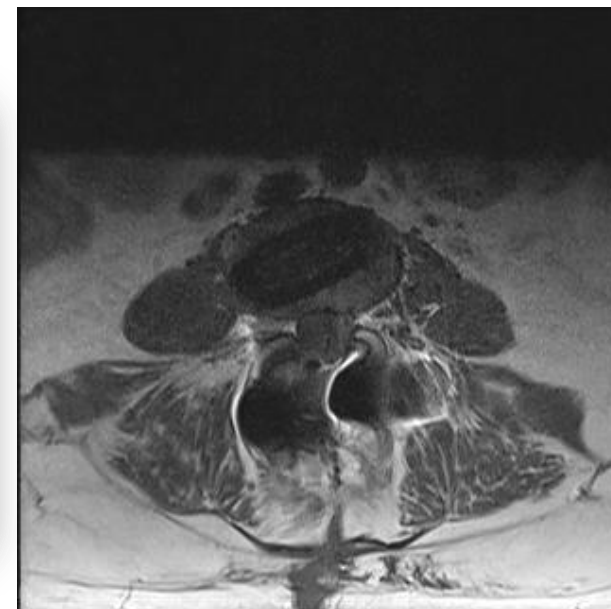
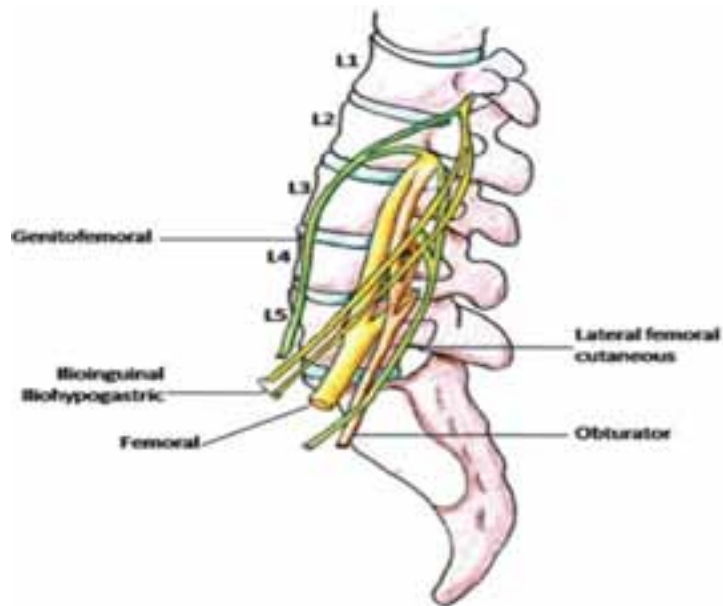
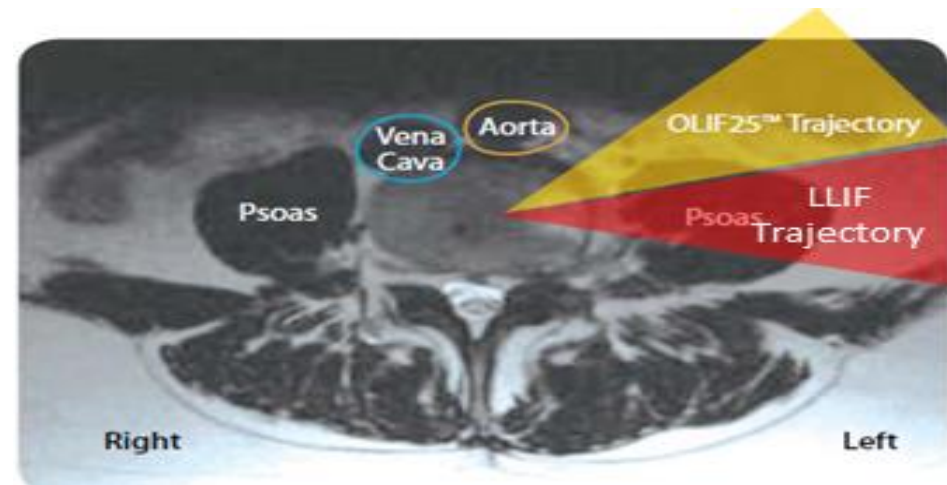
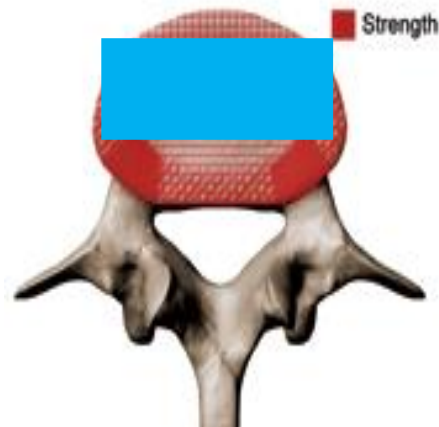


**Allows Larger Fusion Mass**  
允许大面积植骨



# OLIF vs TransPsoas (XLIF/DLIF)

1. Avoid Plexus 避开腰丛神经
2. Avoid psoas stretching 避免腰大肌牵拉
3. Iliac crest not an issue 髂嵴不再是问题
4. Allows sectioning ALL if desired 可离断前纵韧带



# OLIF Clinical Applications

## Indirect Decompression

- Collapsed disc space
- Spondylolisthesis
- Scoliosis deformity

## When Lordosis is Essential

- Kyphoscoliosis correction (Adult Spine Deformity)
- Local Kyphosis (Fusion in lordosis; adjacent level disease)
- Previous Back fusion
- Large PI
- Small PI
- Double Spondylolisthesis
- Thoracic Kyphosis

## When Large or anterior Cage is Desired

- Unstable Spondylolisthesis (anterior shear force)
- Osteoporosis (subsidence)
- High risk for pseudoarthrosis (Adj level, failed fusion, medical)

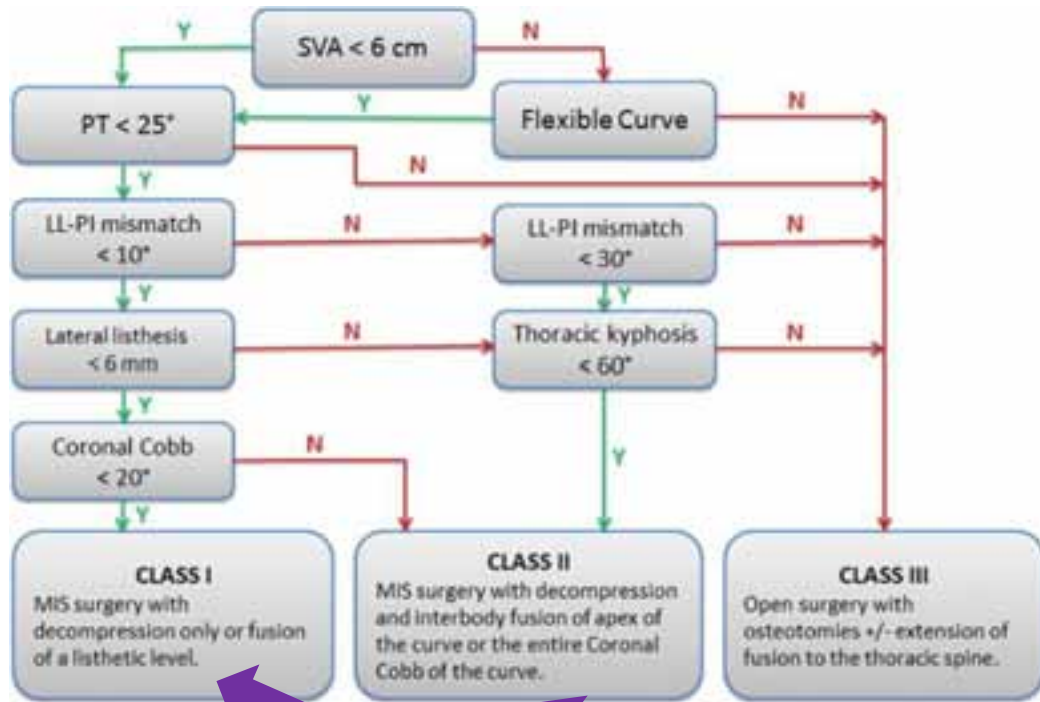
## Miscellaneous

- Previous back surgery with complications (CSF leak, infection)
- When direct decompression is not required

# When to Treat with cMIS, Open, or Hybrid?

The minimally invasive spinal deformity algorithm: a reproducible rational framework for decision making in minimally invasive spinal deformity surgery

Phoebus V. Mitsouras, M.D., Christopher L. Swenson, M.D.,  
 Lawrence S. Lenze, M.D., Fayyaz Khan, M.D., Thomas S. Wilson, M.D.,  
 Frank La Marca, M.D., Joseph S. Sacco, M.D., Giovanni M. Simon Jr., M.D.,  
 Bruce D. Thompson, M.D., Ph.D., Benjamin Weiss, M.D.,  
 William G. Provencher, M.D., Ph.D., Mark Aueron, M.D., Juan S. Uribe, M.D.,  
 Scott S. Korman, M.D., Benjamin Anderson, M.D., and Ravi-Mohan G. Pillai, M.D.,  
 on behalf of the Minimally Invasive Spinal Deformity Section of the International Spinal Study Group



Neurosurg Focus 35 (2):E4, 2013  
 ©AANS, 2013

## Minimally invasive lateral approach for adult degenerative scoliosis: lessons learned

ARMEN R. DEUKMEDJIAN, M.D., AMIR AHMADIAN, M.D., KONRAD BACH, M.D.,  
 ALEXANDROS ZOUZIAS, M.D., AND JUAN S. URIBE, M.D.

Department of Neurosurgery and Brain Repair, University of South Florida, Tampa, Florida

	Mild	Moderate	Severe
CCA	<30°	>30	>30
PI-LL	<20°	20° - 30°	>30°
SVA	<5cm	5 - 9cm	>10cm
PT	<25°	25-30°	>30°
Anterior arthrodesis	Limited MIS-LIF consider standalone if PT<20°	MIS-LIF to neutral vertebrae + ALLR	MIS-LIF to neutral vertebrae ± ALLR
Posterior fixation	Percutaneous fixation	Percutaneous fixation ± facetectomy	Pedicle screw fixation + osteotomy

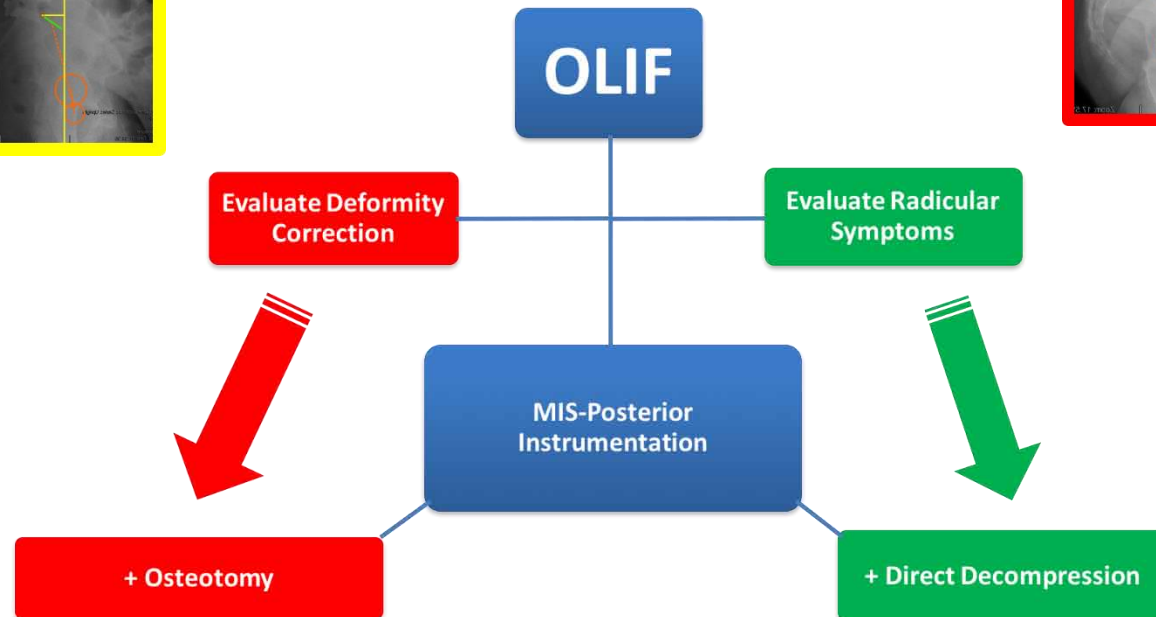
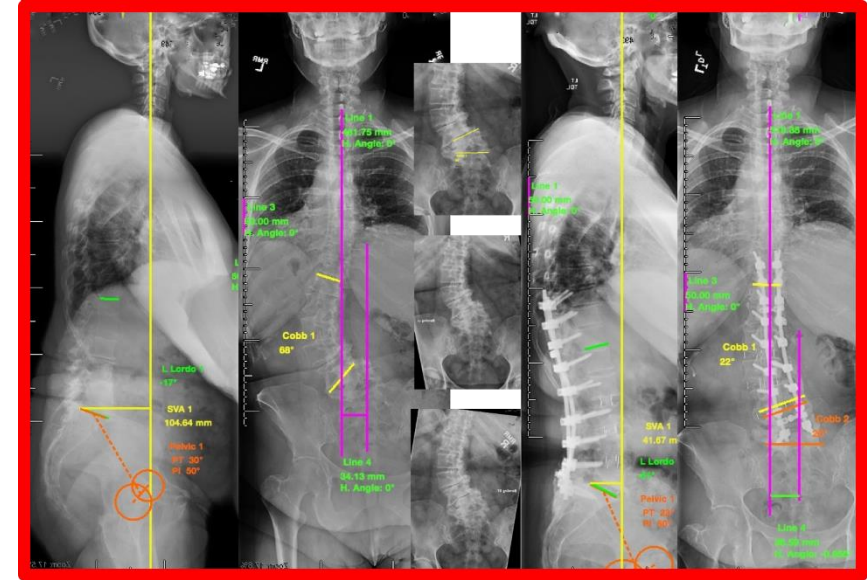
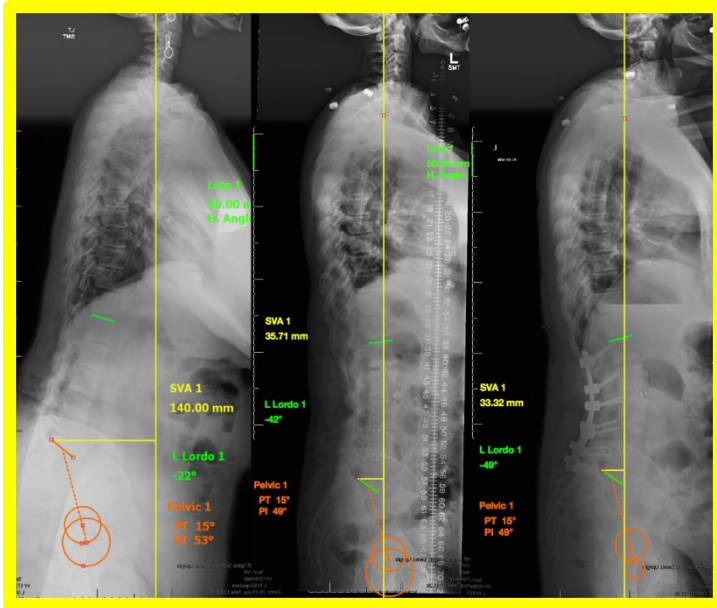
Ponte for SVA<14cm  
 PSO for SVA>14cm

**OLIF**

**HYBRID**

**HYBRID**

# Adult Degenerative Scoliosis



# OLIF Clinical Applications

## Indirect Decompression

- Collapsed disc space
- Scoliosis deformity
- Spondylolisthesis

## When Lordosis is Essential

- Kyphoscoliosis correction
- Local Kyphosis (adjacent level disease)
- Previous Back fusion
- Large PI
- Small PI
- Double Spondylolisthesis
- Thoracic Kyphosis

## When Large or anterior Cage is Desired

- Unstable Spondylolisthesis (anterior shear force)
- Osteoporosis (subsidence)
- High risk for pseudoarthrosis (Adj level, failed fusion, medical)

## Miscellaneous

- Previous back surgery with complications (CSF leak, infection)
- When direct decompression is not required

# Importance of Good Lordosis 恢复前凸的重要性

JNS SPINE

CLINICAL ARTICLE

J Neurosurg Spine 20:420-440, 2017

## Spinopelvic sagittal imbalance as a risk factor for adjacent-segment disease after single-segment posterior lumbar interbody fusion

Tomoya Matsumoto, MD, PhD, Shinya Okuda, MD, PhD, Takafumi Masuo, MD, PhD, Tomoya Yamashita, MD, Ryoji Yamasaki, MD, PhD, Tetsuyoshi Sugiyama, MD, PhD, and Motoki Iwasaki, MD, PhD

Department of Orthopaedic Surgery, Osaka Rosai Hospital, Sakai, Japan

Malalignment = **10x** risk of **ALD** 十倍风险于获得邻近节段退变  
Correct Alignment = better long term outcome

Eur Spine J (2014) 23:1384-1393  
DOI 10.1007/s00586-013-3132-7

ORIGINAL ARTICLE

## Pelvic incidence–lumbar lordosis mismatch results in increased segmental joint loads in the unfused and fused lumbar spine

Marco Senteler · Bernhard Weisse ·  
Jess G. Snedeker · Dominique A. Rothenfluh

**Rate of revision:** PI-LL <15° = 24.4%  
翻修率 PI-LL >15° = **87.2%**

Eur Spine J (2015) 24:1251-1258  
DOI 10.1007/s00586-014-3454-0

ORIGINAL ARTICLE

## Pelvic incidence–lumbar lordosis mismatch predisposes to adjacent segment disease after lumbar spinal fusion

Dominique A. Rothenfluh · Daniel A. Mueller ·  
Esin Rothenfluh · Kan Min

**CONCLUSIONS:** Even with a single-level PLIF, appropriate segment lordosis and LL should be obtained. **Preoperative SVA>50 and a higher PT, PI and PI-LL mismatch were significantly associated with ALD** 研究表明，术前SVA>50,以及PT,PI和PI-LL差值大的病患很容易引发邻近节段退变

Spine

CLINICAL CASE SERIES

SPINE, Volume 40, Number 14, pp 1841-1844  
©2015, Wolters Kluwer Health, Inc. All rights reserved.

## Adjacent Segment Disease After Posterior Lumbar Interbody Fusion

Based on Cases With a Minimum of 10 Years of Follow-up

Hiraki Nakashima, MD,\*† Noriaki Kawakami, MD, DMSc,\* Taichi Tsuji, MD, DMSc,\* Tetsuya Ohara, MD,\* Yoshitaka Suzuki, MD, DMSc,\* Toshiaki Saito, MD, DMSc,\* Ayato Nohara, MD,\* Ryoji Tauchi, MD, DMSc,\* Kyotaro Ohta, MD,\* Nobuyuki Hamajima, MD, PhD, MPH,† and Shiro Imagama, MD, DMSc†

**Conclusion.** Obtaining appropriate **lumbar lordosis in PLIF is important for preventing ALD., especially in high PI**  
获得适当的腰椎前凸，对后路PLIF手术成功与否起着关键作用，特别是有着PI值较大的病患



# Why OLIF not TLIF for Lordosis?

为什么OLIF在恢复前凸方面表现更优异

## Comparison of Minimal Invasive Transforaminal Lumbar Interbody Fusion with Oblique Lumbar Interbody Fusion for L4-5: Clinical and Radiological Outcomes

Presented at SOTCS Annual Forum 2018  
By Hyun-Jin Jo  
With Jin-Sung Kim MD, PhD

**Conclusions: OLIF has higher potential in increasing postoperative disc height and decreasing postoperative subsidence.** 能更好地恢复间盘高度减少沉降



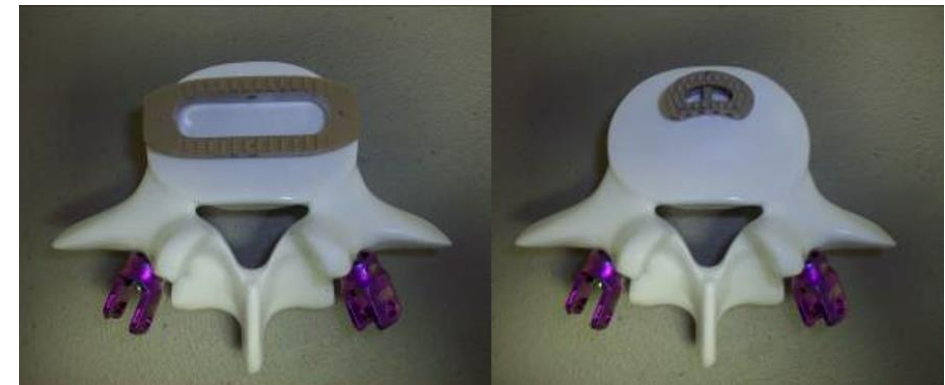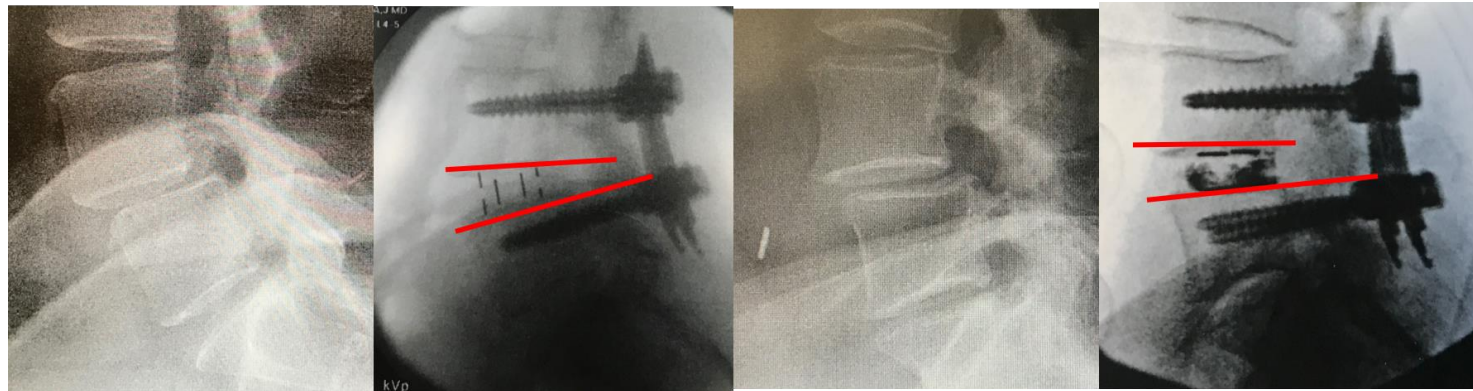
**MIS-TLIF** group had

- 1. less** improvement of **discal height** 间盘高度恢复没有OLIF理想
- 2. larger** degree of postoperative implant **settling** 更多融合器沉降可能性
- 3. less** mean **foraminal increase** particularly on the contralateral side. 对侧减压效果差

Reconstructive Technique	Segmental Alignment (Lordosis)
PL Fusion	-10° - 0° (Dimar et al)
<b>TLIF/PLIF</b>	<b>-0.1° - -6° (Hsieh et al)</b>
TLIF/PLIF + Grade I Osteotomy	7° - 8° (Yson et al)
TLIF/PLIF + Grade II Osteotomy	15° - 20°
<b>OLIF</b>	<b>1.2° - 3.6°</b>
OLIF + Grade II Osteotomy	25° - 30°
<b>OLIF + Release of ALL*</b>	<b>10° - 20° (50% of cage lordosis)</b>
OLIF + Release of ALL* + Grade II Osteotomy	20° - 30° (100% of cage lordosis)

\* ALL release not effective for non-flexible segment (fused, calcified disc, ankylosed facet)

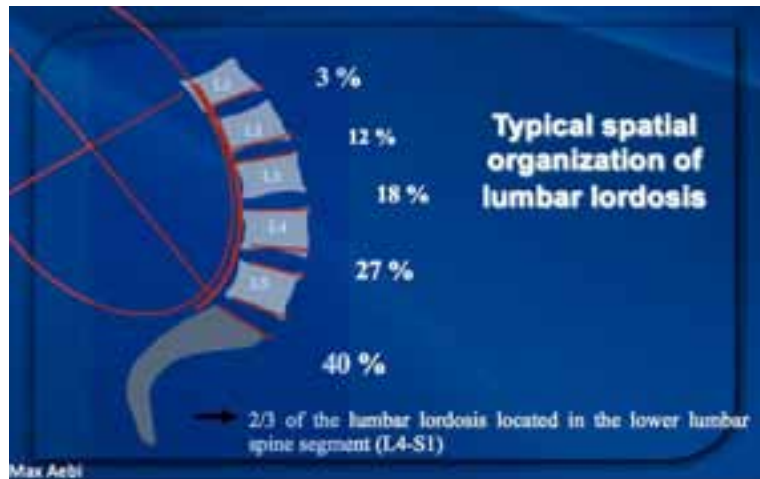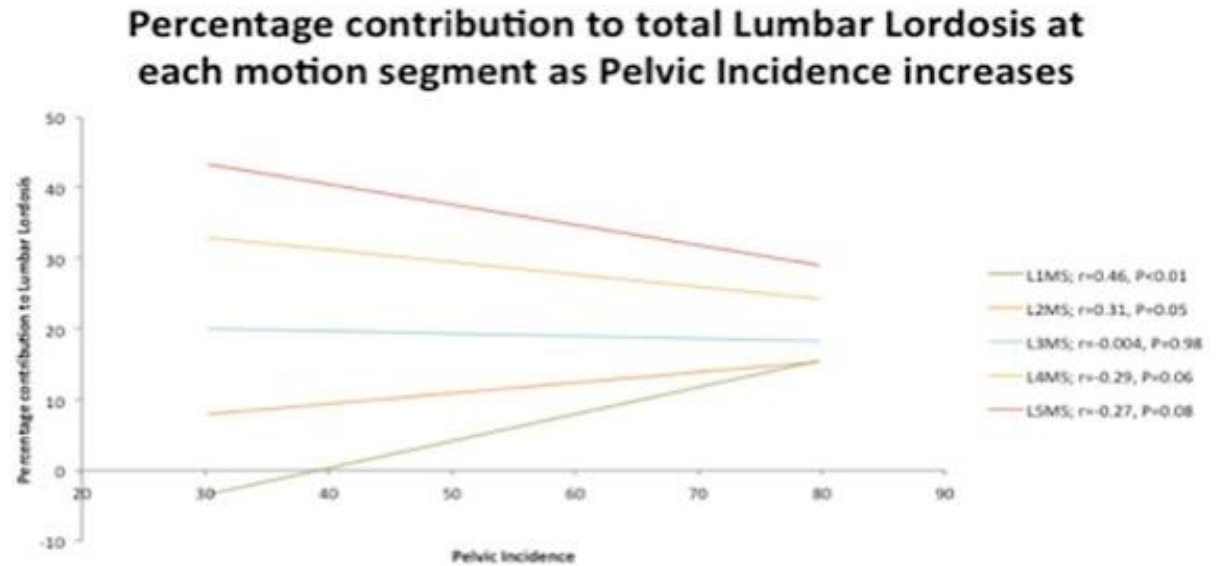
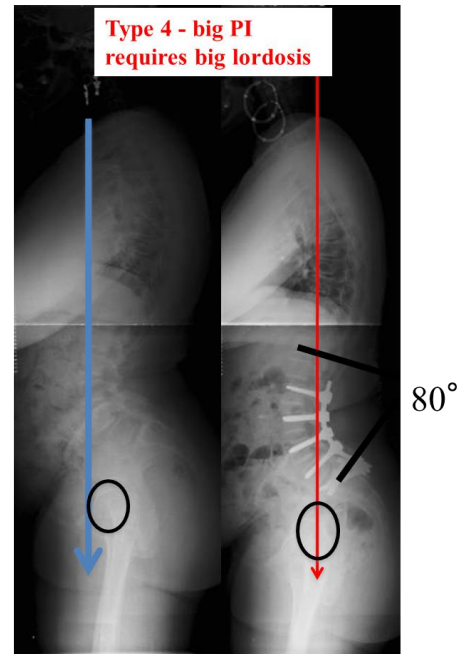
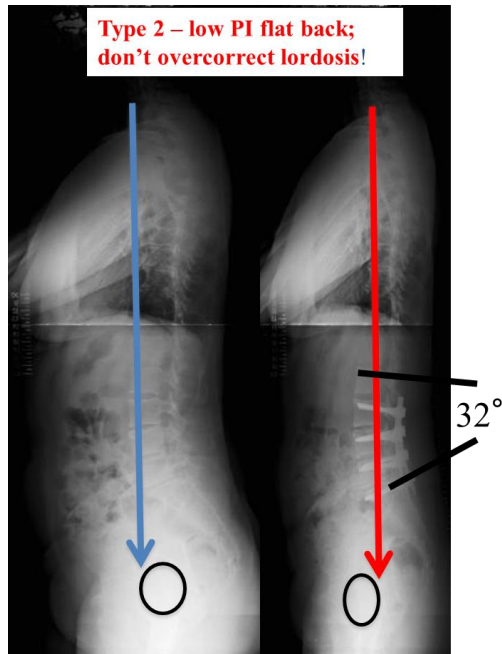
**OLIF has less subsidence than TLIF**



Clydesdale® Spinal System  
**OLIF**

Crescent® Spinal System  
**TLIF**

# OLIF Lordosis: Large PI



In large PI, other segments other than L4-S1 start playing a more significant role in lordosis  
 PI角度大的病患，L4-S1外的节段对前凸起到更大的作用

# OLIF Lordosis: Double Spondylolisthesis

Eur Spine J (2016) 25:2546–2552  
DOI 10.1007/s00586-016-4384-9

ORIGINAL ARTICLE

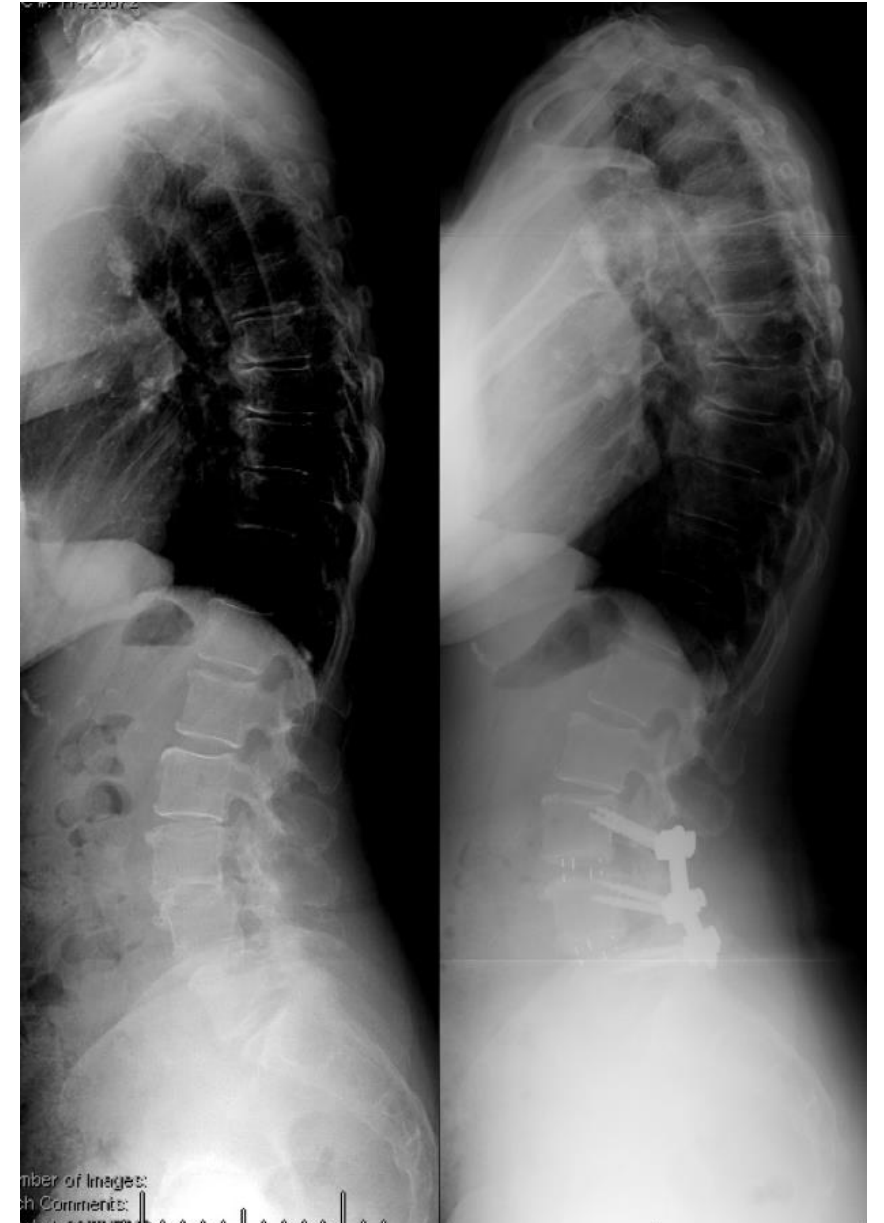## Double-level degenerative spondylolisthesis: what is different in the sagittal plane?

Emmanuelle Ferrero<sup>1</sup> · Anne-Laure Simon<sup>2</sup> · Baptiste Magrino<sup>1</sup> · Mourad Ould-Silmane<sup>3</sup> · Pierre Guigui<sup>1</sup>

**Conclusions MultiLevel DS have different sagittal alignment than single DS with greater PI**

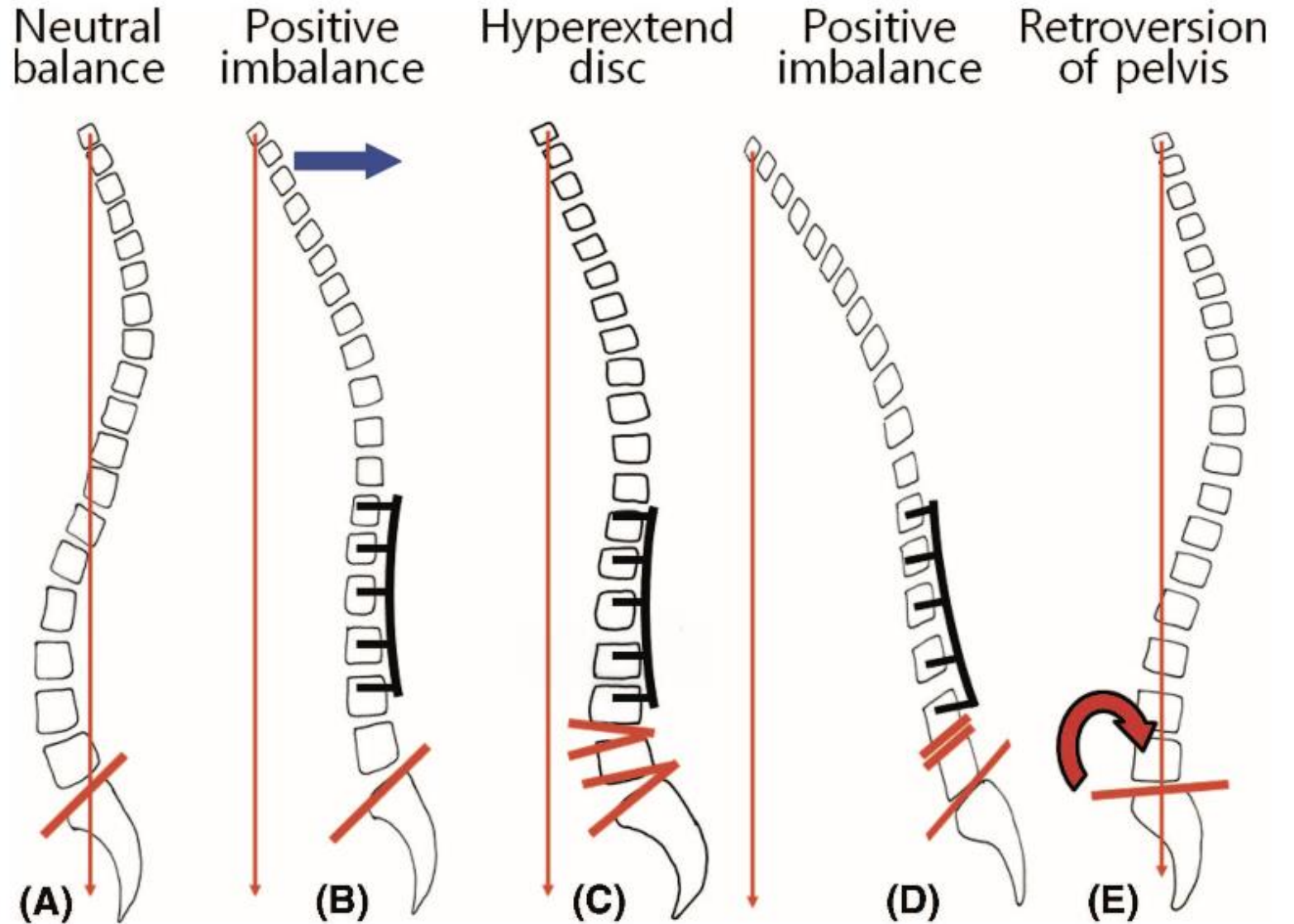
多节段滑脱的病患同单节段滑脱且PI角度大的病患相比，矢状位对线不一致

**It is imperative to fuse in lordosis in patients with DS**  
多节段滑脱病患一定要在前凸处融合

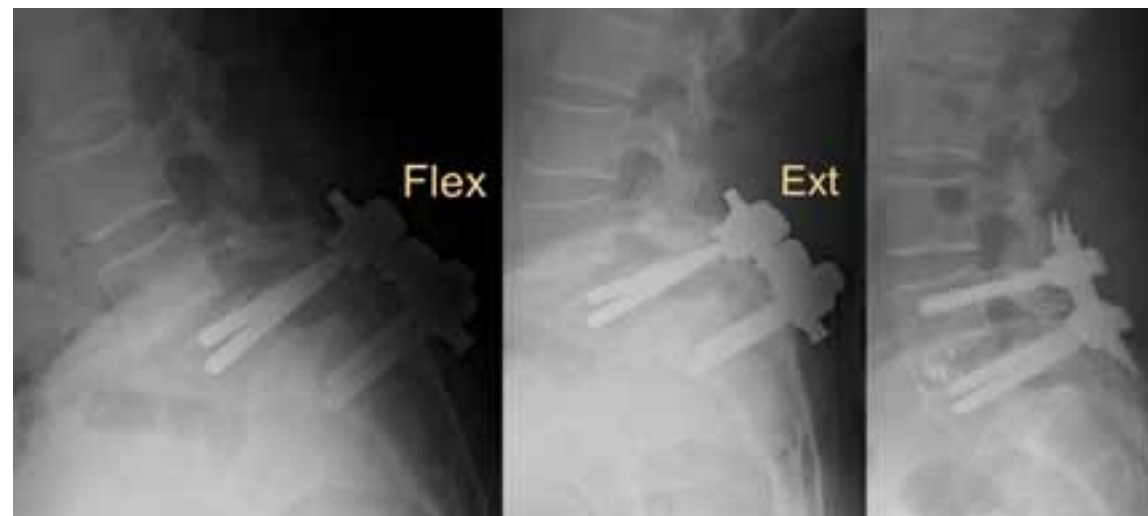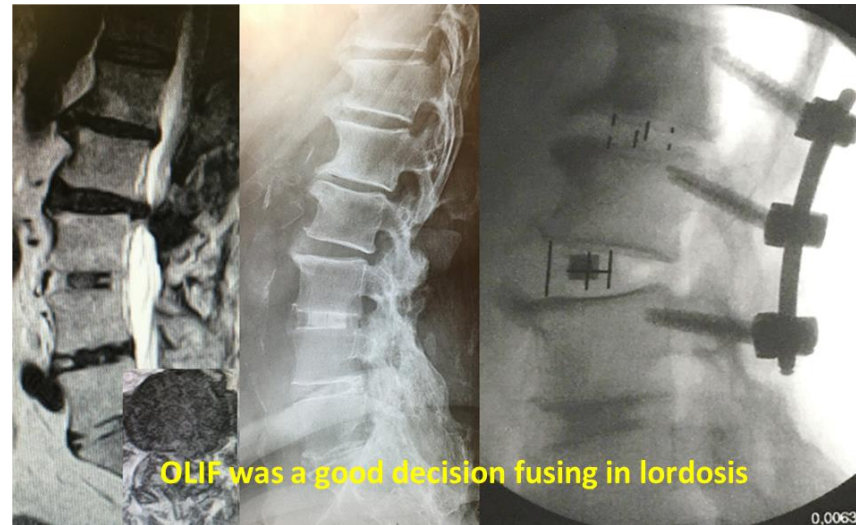
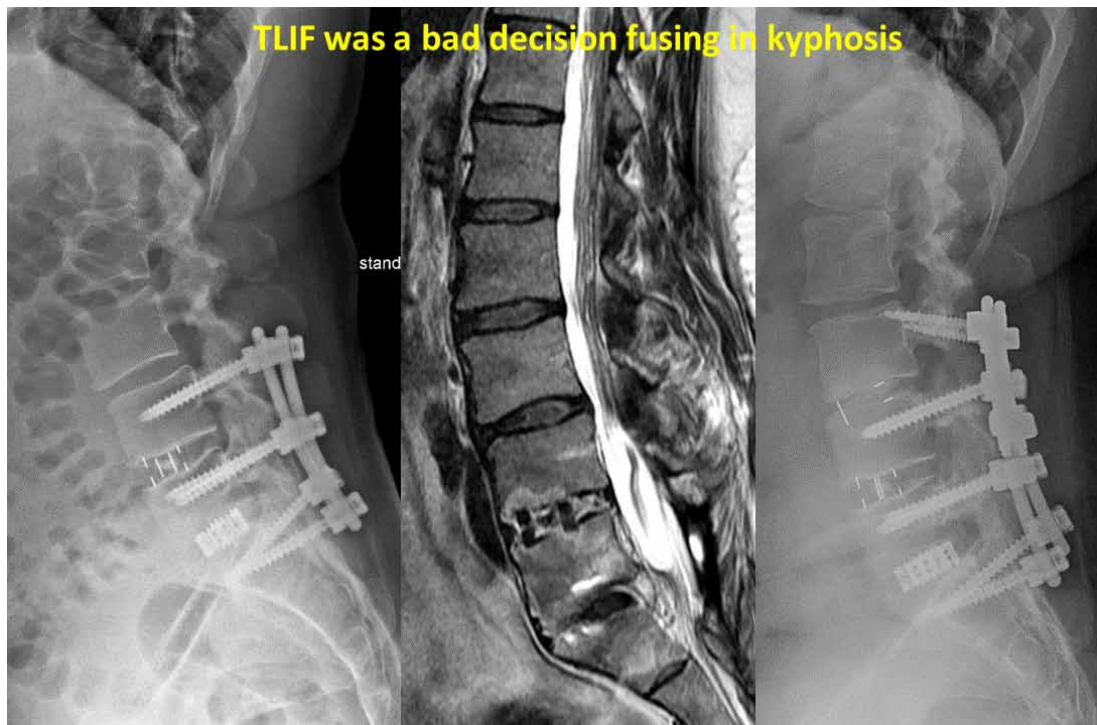


# OLIF Lordosis: Previous Fusion

Losing lordosis adjacent to hypolordotic fusion eliminates the initial subtle compensatory mechanisms decompressing patient  
在邻近前凸不足处丢失前凸，将使得代偿功能减少



# OLIF Lordosis: Previous Fusion



# OLIF Clinical Applications

## Indirect Decompression

- Collapsed disc space
- Spondylolisthesis
- Scoliosis deformity

## When Lordosis is Essential

- Kyphoscoliosis correction (Adult Spine Deformity)
- Local Kyphosis (Fusion in lordosis; adjacent level disease)
- Previous Back fusion
- Large PI
- Small PI
- Double Spondylolisthesis
- Thoracic Kyphosis

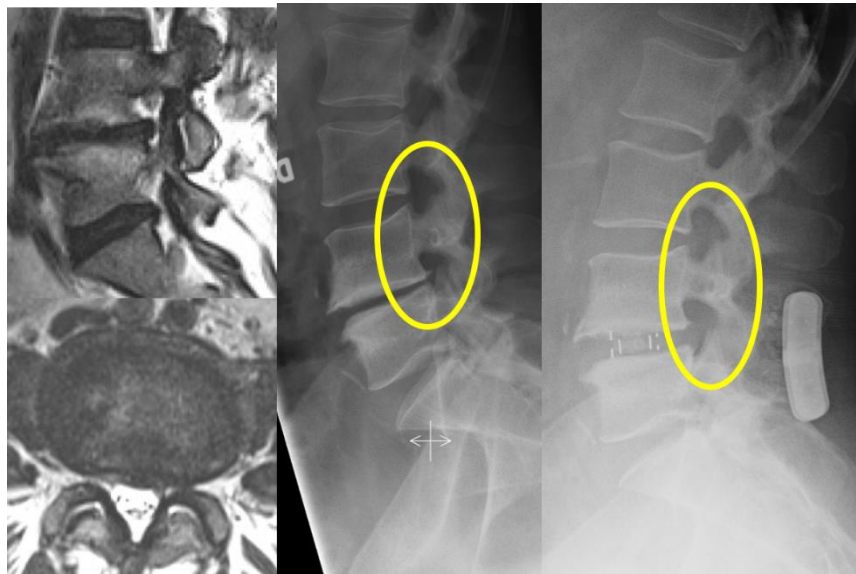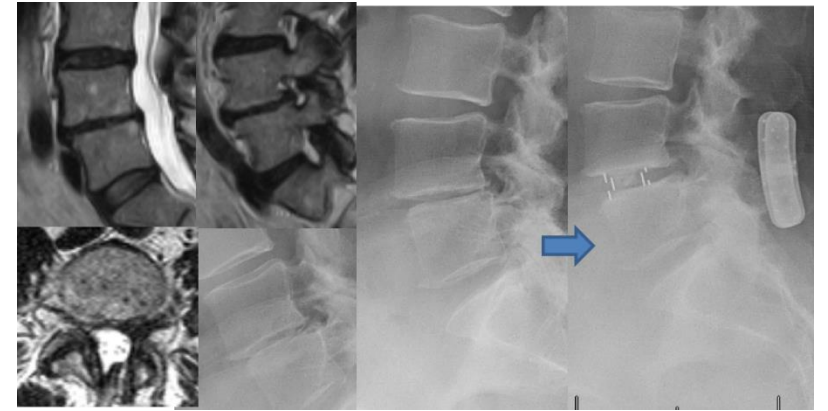
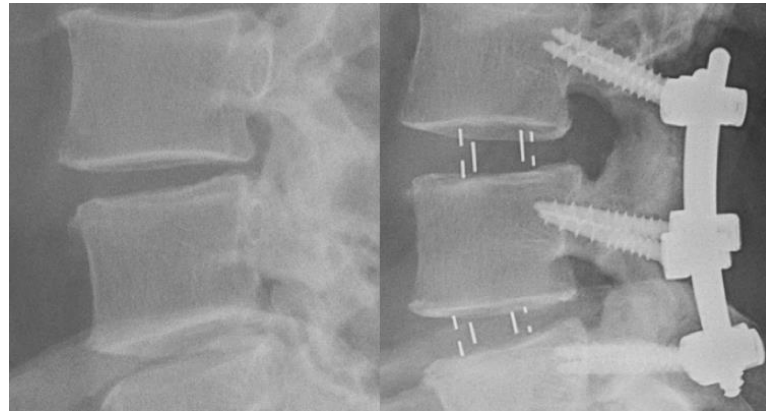
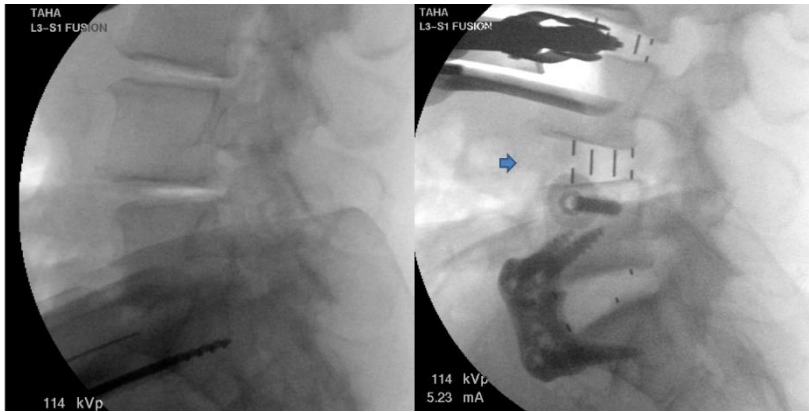
## When Large or anterior Cage is Desired

- Unstable Spondylolisthesis (anterior shear force)
- Osteoporosis (subsidence)
- High risk for pseudoarthrosis (Adj level, failed fusion, medical)

## Miscellaneous

- Previous back surgery with complications (CSF leak, infection)
- When direct decompression is not required

# Indirect Foraminal Decompression: Collapsed Disc



## Why not MIS-TLIF?

Comparison of Minimal Invasive Transforaminal Lumbar Interbody Fusion with Oblique Lumbar Interbody Fusion for L4-5: Clinical and Radiological Outcomes

Presented at SOTSS Annual Forum 2018  
By Hyun-Jin Jo  
With Jin-Sung Kim MD, PhD

Conclusions: **OLIF** has higher potential in increasing postoperative disc height and decreasing postoperative subsidence.

# Indirect Foraminal Decompression: Spondylolisthesis

Eur Spine J (2017) 26:673–678  
DOI 10.1007/s00586-017-4370-0



ORIGINAL ARTICLE

## Radiographic evaluation of indirect decompression of mini-open anterior retroperitoneal lumbar interbody fusion: oblique lateral interbody fusion for degenerated lumbar spondylolisthesis

Jun Sato<sup>1</sup> · Seiji Ohtori<sup>2</sup> · Numbira Grita<sup>3</sup> · Kazuyo Yamashita<sup>1</sup> · Yawara Egochi<sup>1</sup> · Nobuyasu Ochiai<sup>1</sup> · Kazuki Kamiyoshi<sup>1</sup> · Yasuchika Aoki<sup>1</sup> · Junichi Nakamura<sup>2</sup> · Masayuki Miyagi<sup>1</sup> · Miyako Suzuki<sup>2</sup> · Gou Kobota<sup>1</sup> · Kazuhide Inagi<sup>1</sup> · Takeshi Saitoh<sup>1</sup> · Kazuki Fujimoto<sup>1</sup> · Yashiro Shiga<sup>1</sup> · Koki Ake<sup>2</sup> · Hirota Kanamoto<sup>1</sup> · Gen Inoue<sup>1</sup> · Kazuhisa Takahashi<sup>1</sup>

Received: 17 March 2017 / Revised: 28 July 2017 / Accepted: 28 July 2017 / Published online: 6 August 2017  
© Springer Science+Business Media Dordrecht 2017

	Before surgery	After surgery	P
Low back pain			
Visual analogue scale score	5.5 ± 1.9	1.9 ± 0.9	0.02
Oswestry Disability Index	50 ± 16	16 ± 8	0.033
Leg pain			
Visual analogue scale score	8.1 ± 3.3	2.0 ± 0.7	0.01
Leg numbness			
Visual analogue scale score	6.0 ± 2.0	3.1 ± 1.2	0.04

Spine

SURGERY

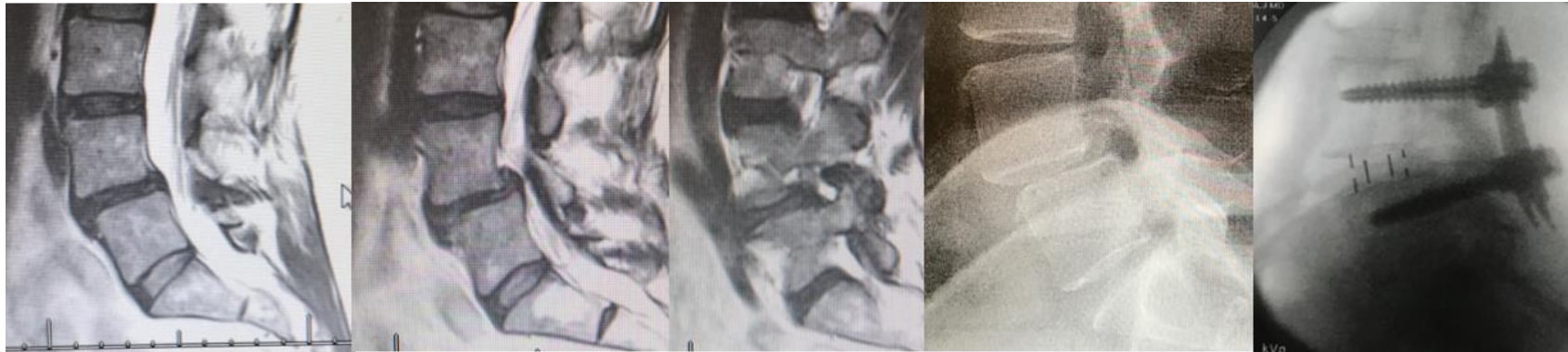Spine Volume 41, Number 16, pp 1111–1114  
© 2014 Wolters Kluwer Health | Lippincott Williams & Wilkins

## Two-Year Comparative Outcomes of MIS Lateral and MIS Transforaminal Interbody Fusion in the Treatment of Degenerative Spondylolisthesis

Part II: Radiographic Findings

Robert E. Isaacs, MD,<sup>1</sup> Jonathan H. Sembrano, MD,<sup>1,2</sup> Antoine C. Tahmah, MD<sup>1</sup>, and SOLAS Degenerative Study Group

- MIS-TLIF** group had
- 1. less** improvement of **discal height**  
间盘高度恢复没有OLIF理想
  - 2. larger** degree of postoperative implant **settling** 更多融合器沉降可能性
  - 3. less** mean **foraminal increase**  
particularly on the contralateral side. 对侧减压效果差

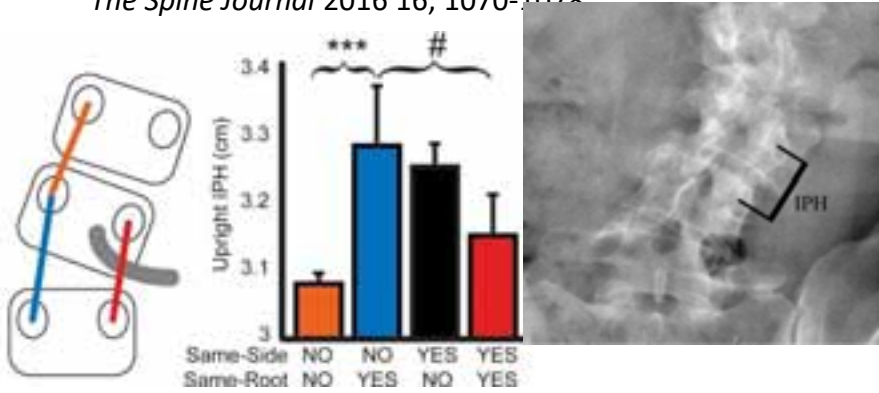




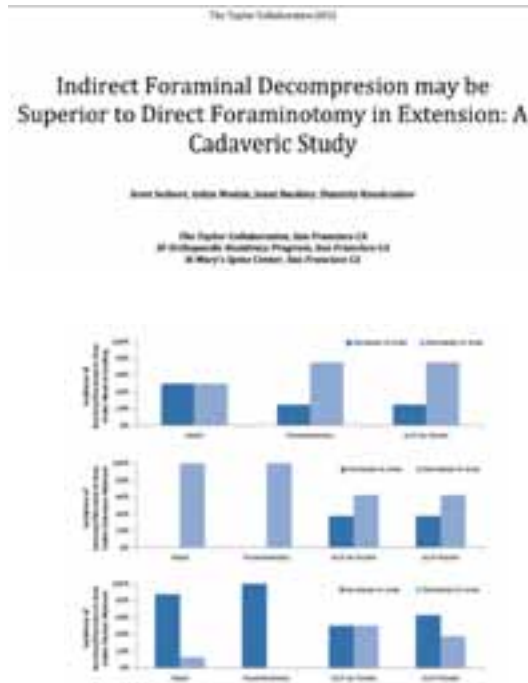
# Indirect Foraminal Decompression: Scoliosis

Leg pain related to foramen stenosis caused by ↓ disc height & coronal tilt  
 间盘高度丢失引起的椎间狭窄及冠状位失衡会引发腿痛

The Spine Journal 2016 16, 1070-1078



## Why not MIS-Foraminotomy?

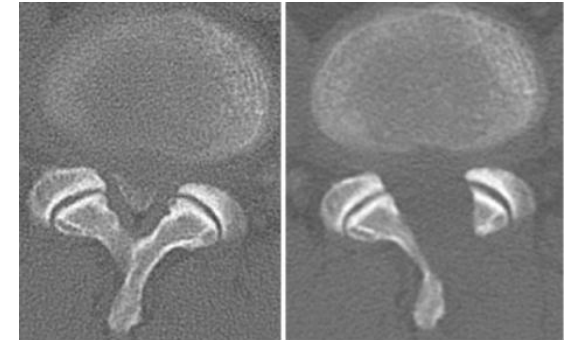


JNS<sub>SPINE</sub>

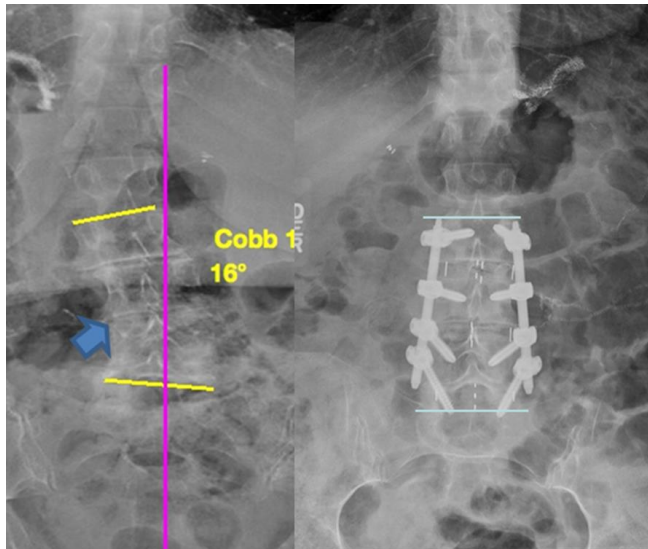
The influence of preoperative spinal sagittal balance on clinical outcomes after microendoscopic laminotomy in patients with lumbar spinal canal stenosis

Sho Dohtani, MD, PhD,<sup>1</sup> Hiromitsu Toyoda, MD, PhD,<sup>2</sup> Tomiya Matsumoto, MD, PhD,<sup>1</sup> Akinobu Suzuki, MD, PhD,<sup>1</sup> Hirotomi Terao, MD, PhD,<sup>1</sup> and Hiroaki Nakamura, MD, PhD<sup>1</sup>

<sup>1</sup>Department of Orthopaedic Surgery, Osaka City University Graduate School of Medicine, and <sup>2</sup>Department of Orthopaedic Surgery, Osaka Prefecture Hospital, Osaka, Japan

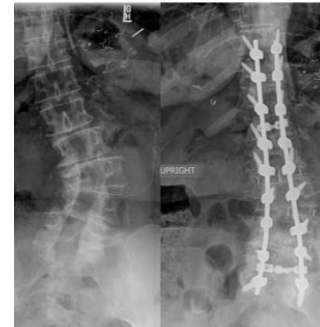

**CONCLUSIONS:** LBP was worse for patients with preoperative positive balance than for those without.



**Conclusion:** Lumbar interbody fusion maintains the foraminal area in extension while direct foraminotomy may not.  
 椎间融合器能稳定撑开椎间隙

Even more valuable in previous back decompression surgery  
 在过去减压过的手术中更有价值



***Thanks ! !***